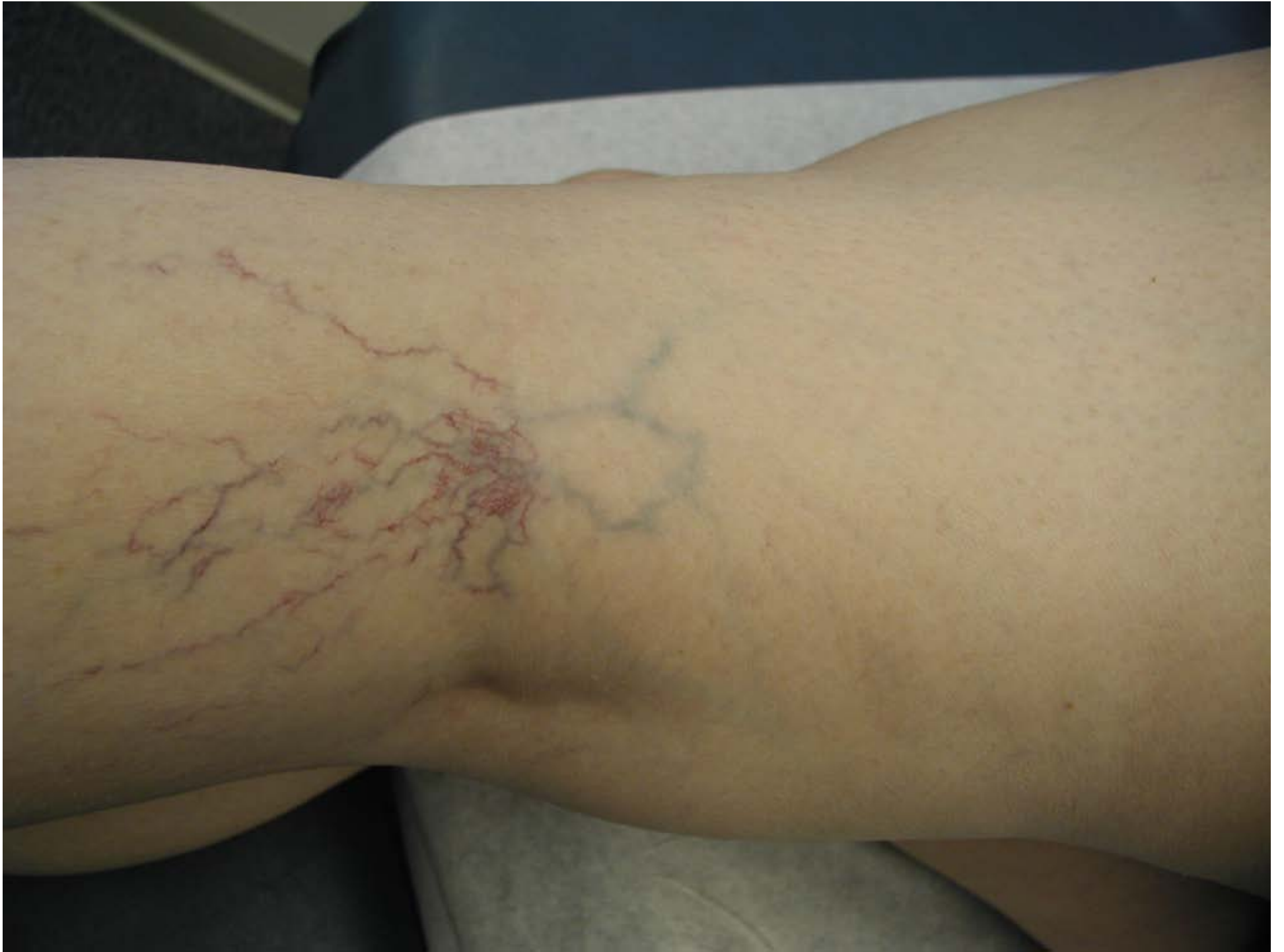

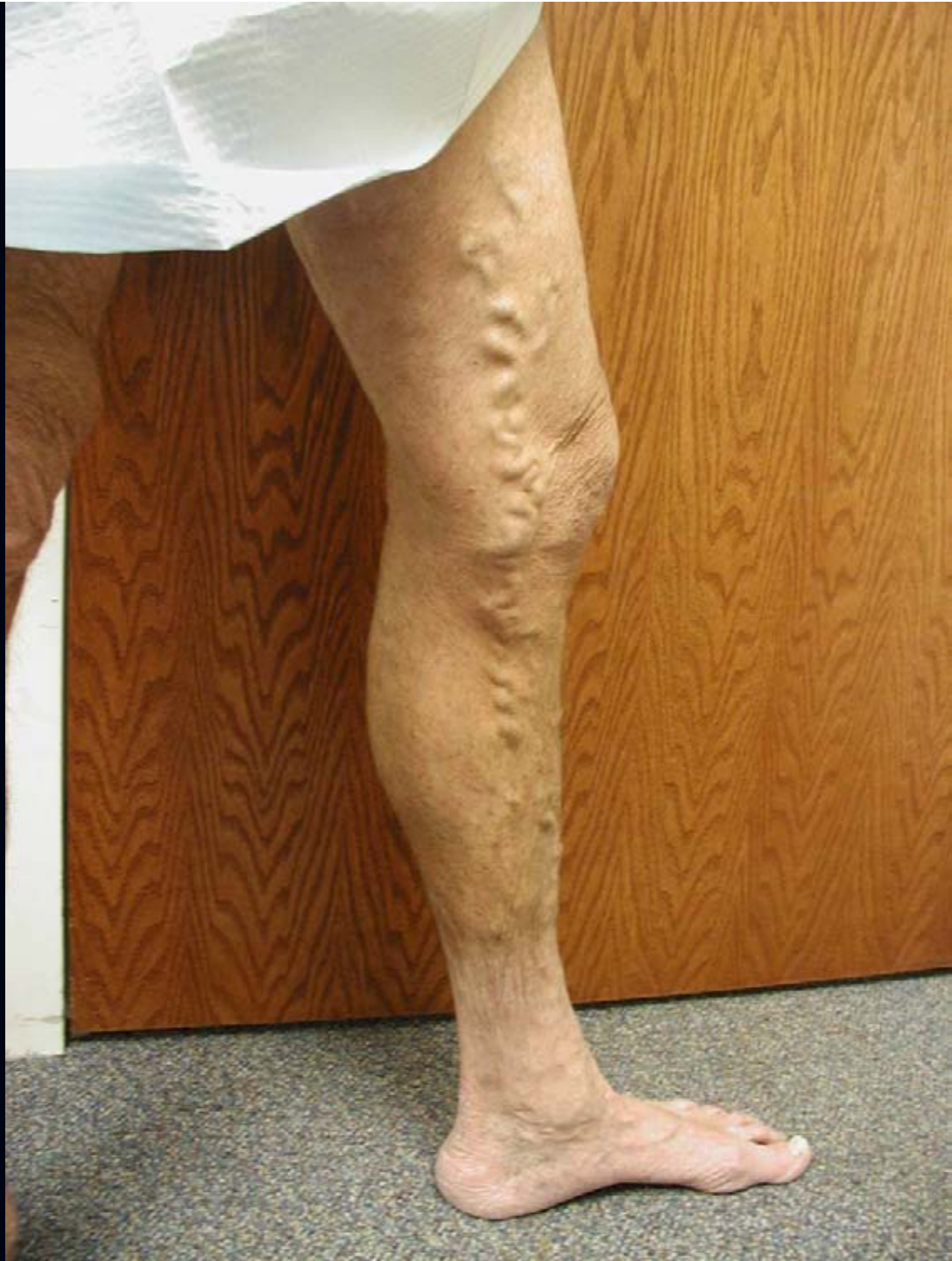# How to Evaluate a Phlebology Patient

John F. Golan, M.D.  
Chief, Division of Vascular Surgery  
Evanston Northwestern Healthcare  
Evanston, Illinois

# Venous Disease Definitions

- Varicose Vein – Dilated, protruding, tortuous, saccular superficial veins in subcutaneous tissue
- Reticular Vein – Dilated, tortuous, non-protruding superficial veins in subcutaneous tissue
- Telangiectasia – Spider appearing, tortuous, non-protruding or dilated veins in dermis





# Varicose Veins

## ■ Primary vs. Secondary

### ■ Primary

- Incompetence arises in the venous system from non-obstructive causes( hereditary, hormonal, etc)

### ■ Secondary

- Incompetence arises in deep venous system (usually due to prior thrombosis)--deep veins obstructed perforators dilate and become incompetent

# Varicose Veins

## Medical Consequences

- Superficial Venous Thrombophlebitis
- Deep Vein Thrombosis
- Venous Stasis/Ulceration
- Bleeding
- Spider Angiomas

# Varicose Veins-Symptoms

- Aching
- Vague Discomfort
- Heat/Burning
- ? Swelling

All tend to increase with dependency and resolve with leg elevation or compression

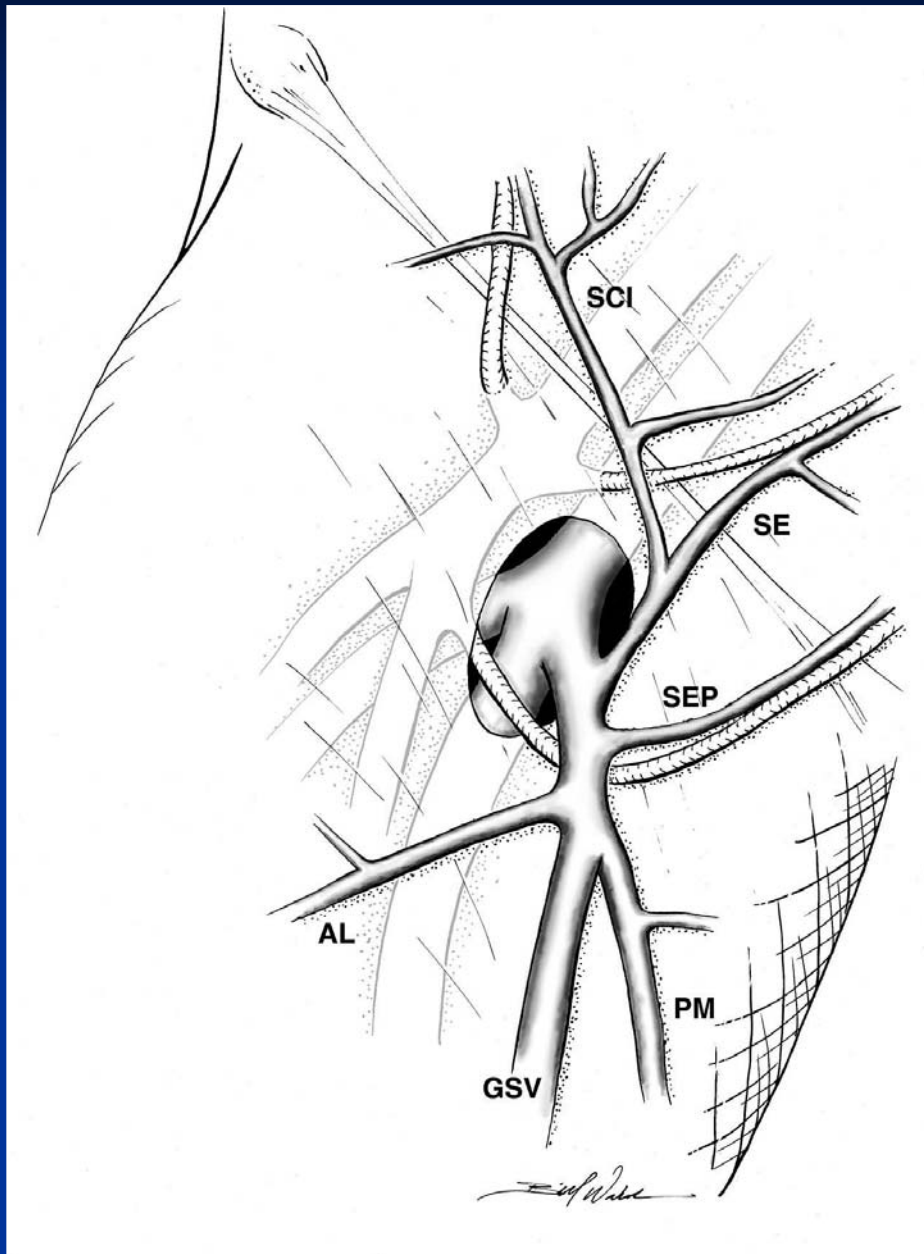
# Primary Varicose Veins

- Incompetent Saphenofemoral Junction
- Incompetent Saphenopopliteal Junction
- Incompetent Perforators

# Varicose Veins-Physical Exam

- Varicose vs. Spider
- Distribution-Greater, Lesser or Branches
- Size
- Stasis Changes
- Edema

# Tributaries at the SFJ



## Tributary Legend

AL – Anterolateral

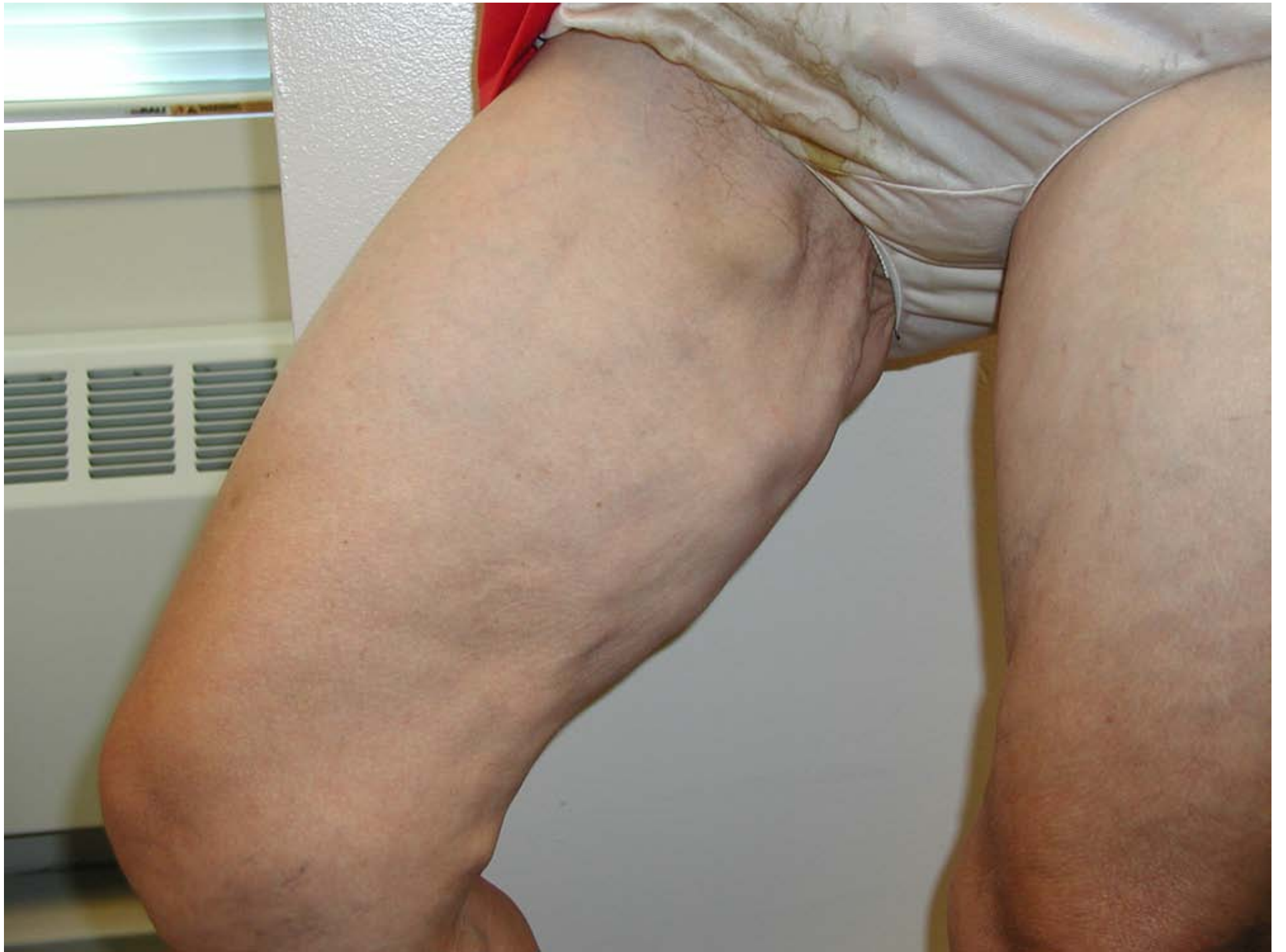PM – Posteromedial

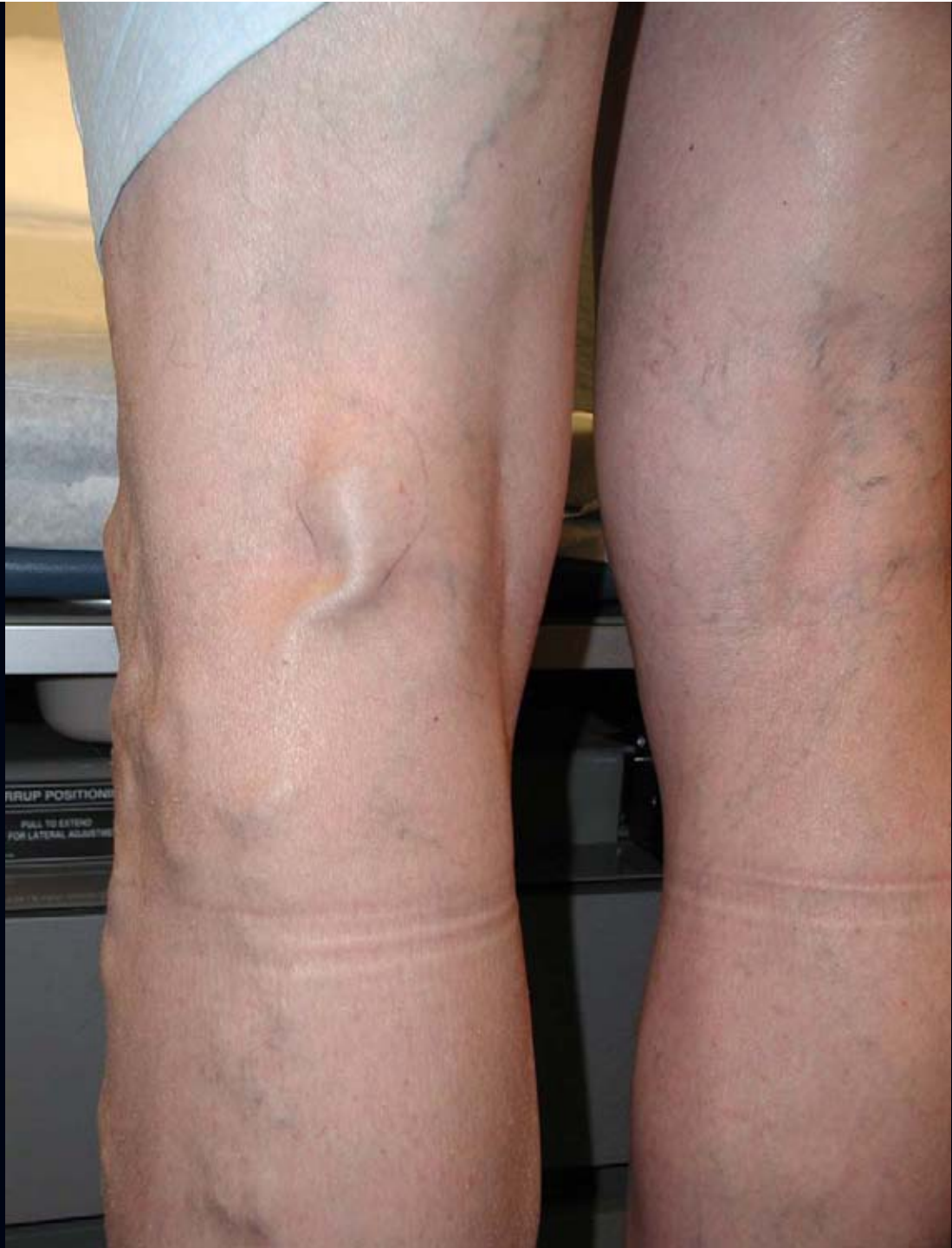SEP – Superficial external pudendal

SE – Superficial epigastric

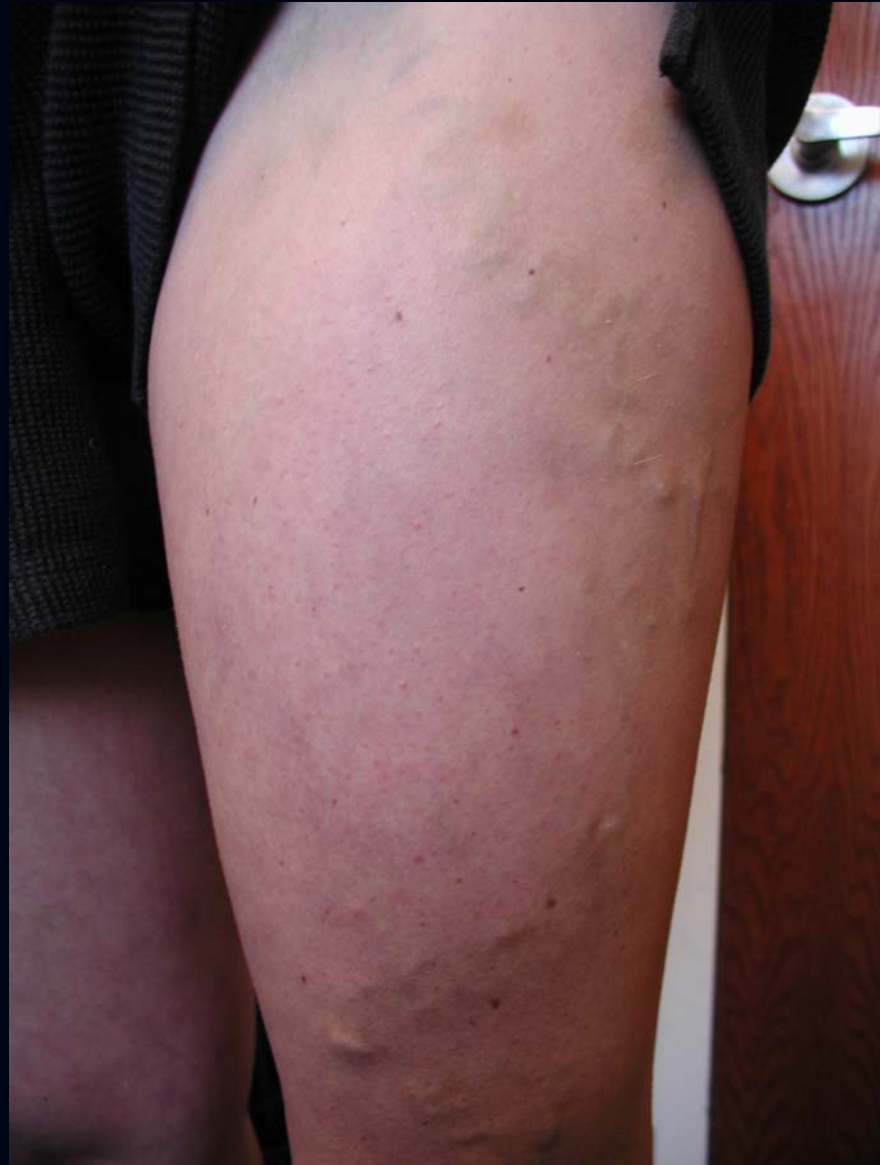SCI – Superficial circumflex iliac

- Anterolateral branch often demonstrates reflux alone
- Posteromedial branch when dilated is called the vein of Giacomini

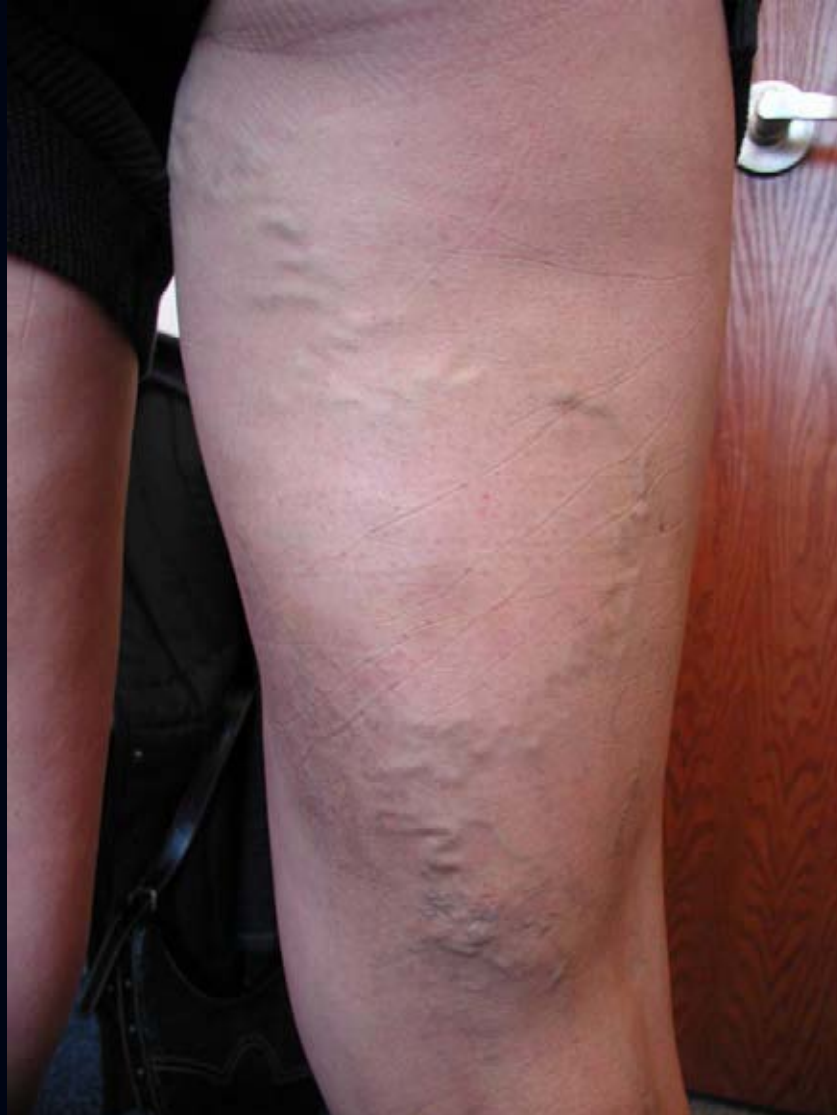

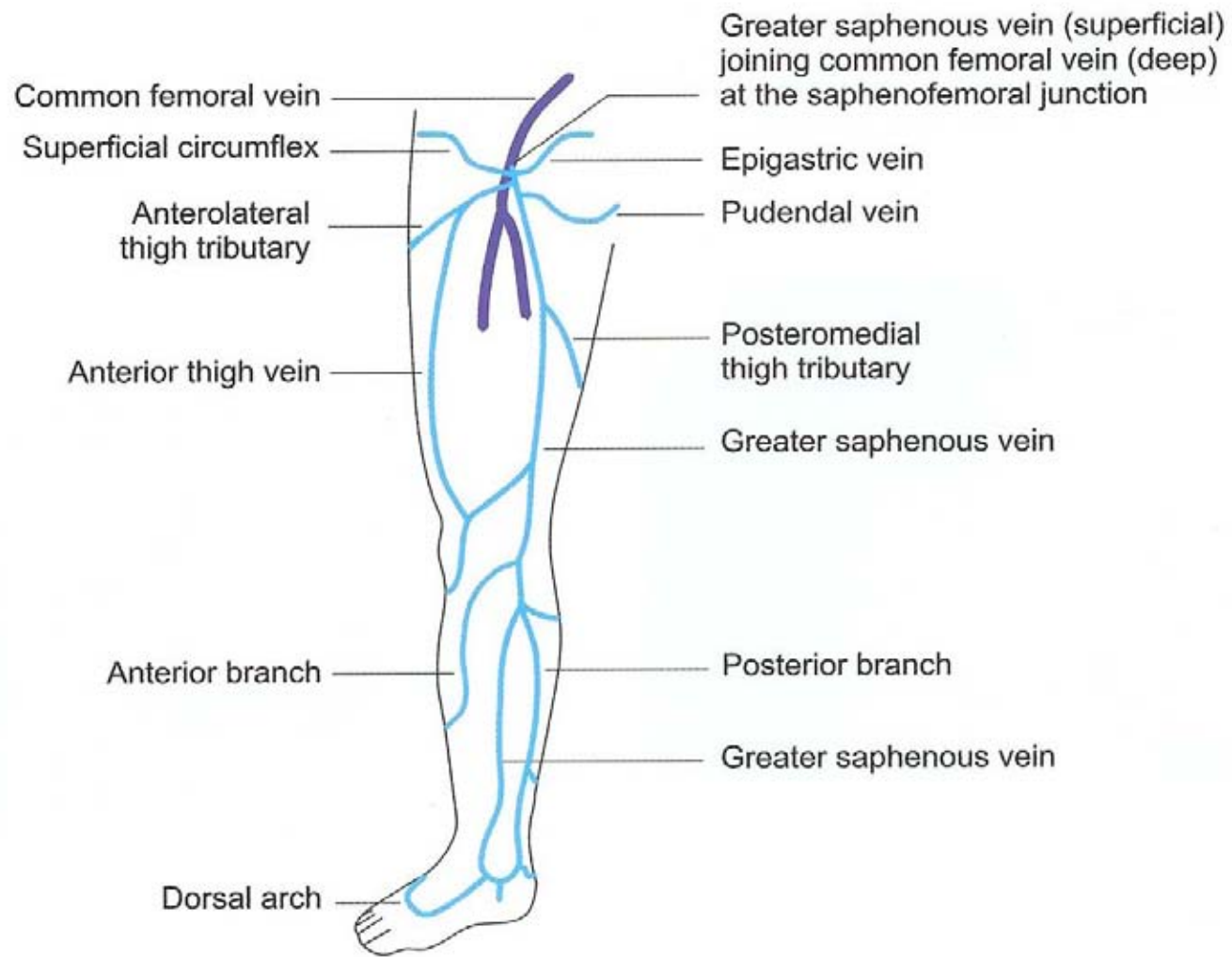


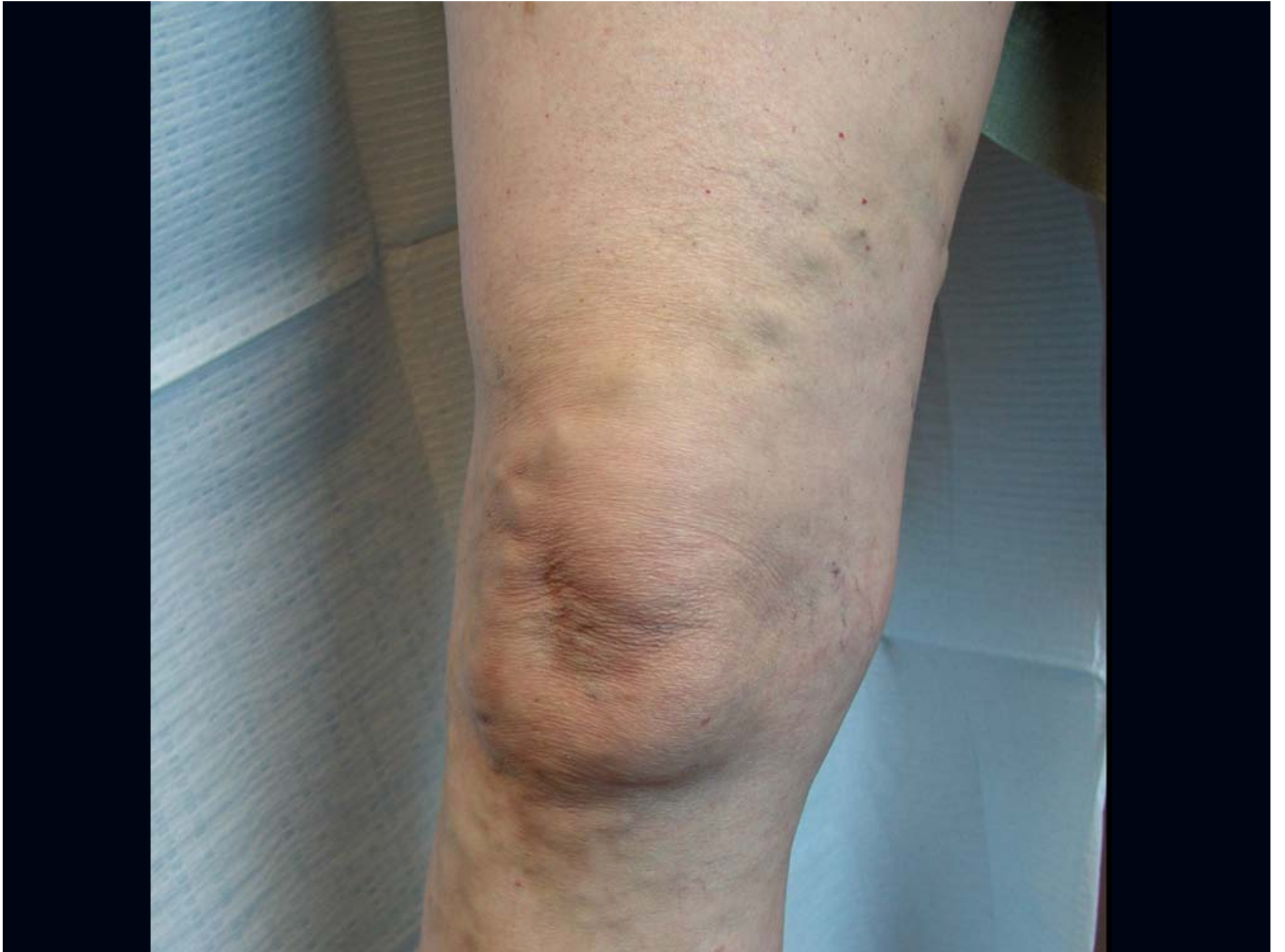# Anterior Lateral Branch

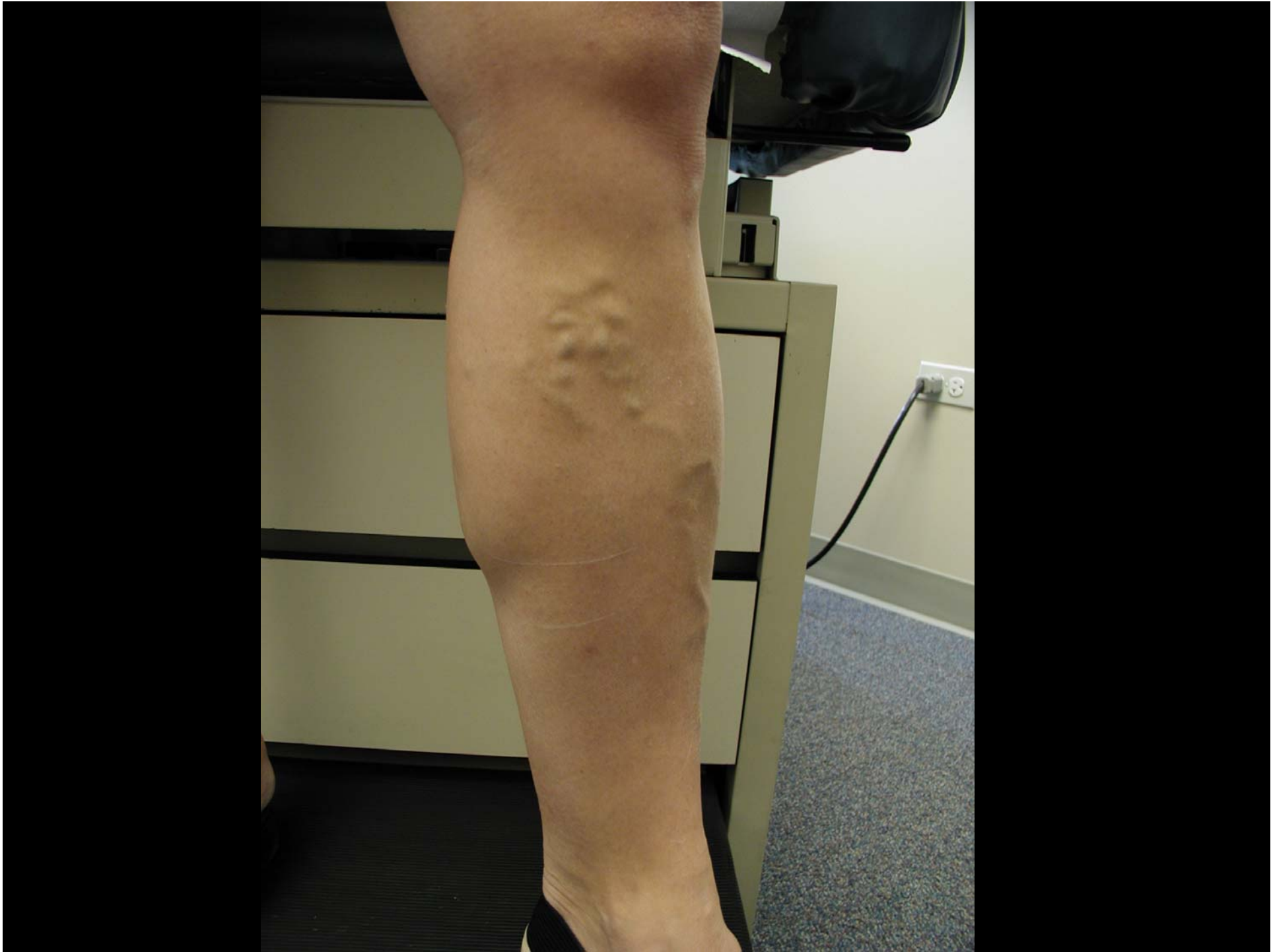

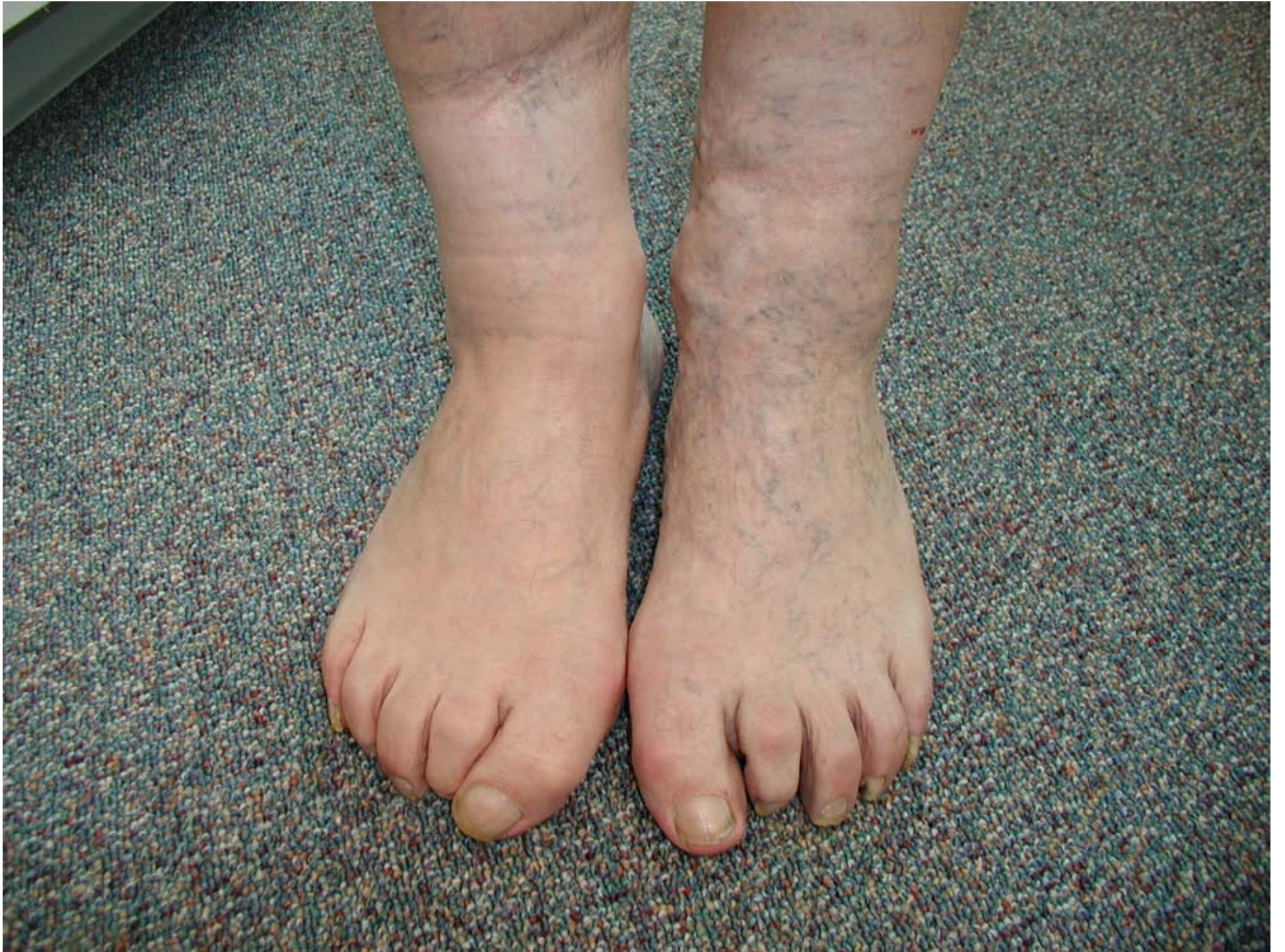# Posterior Medial Branch

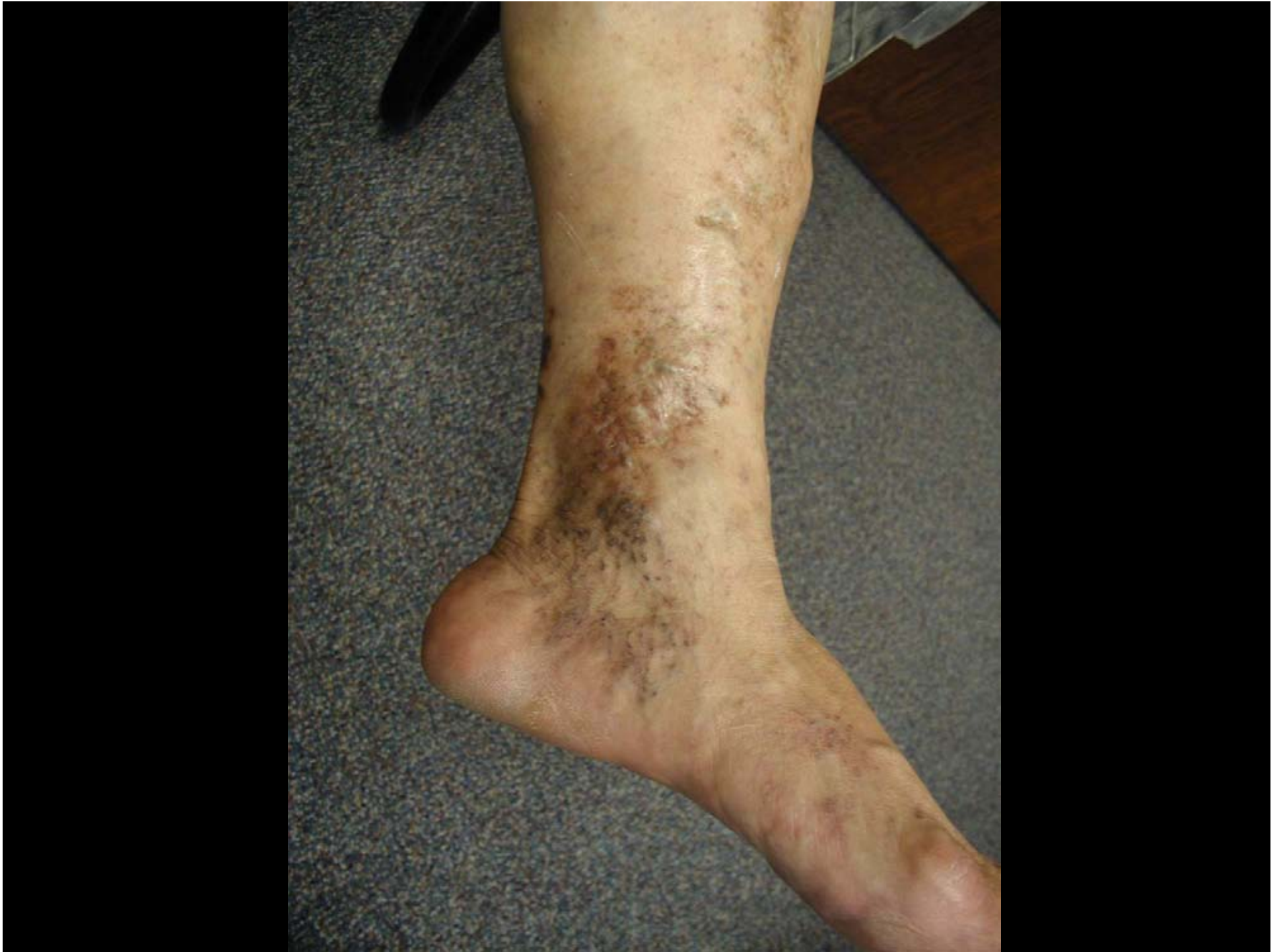



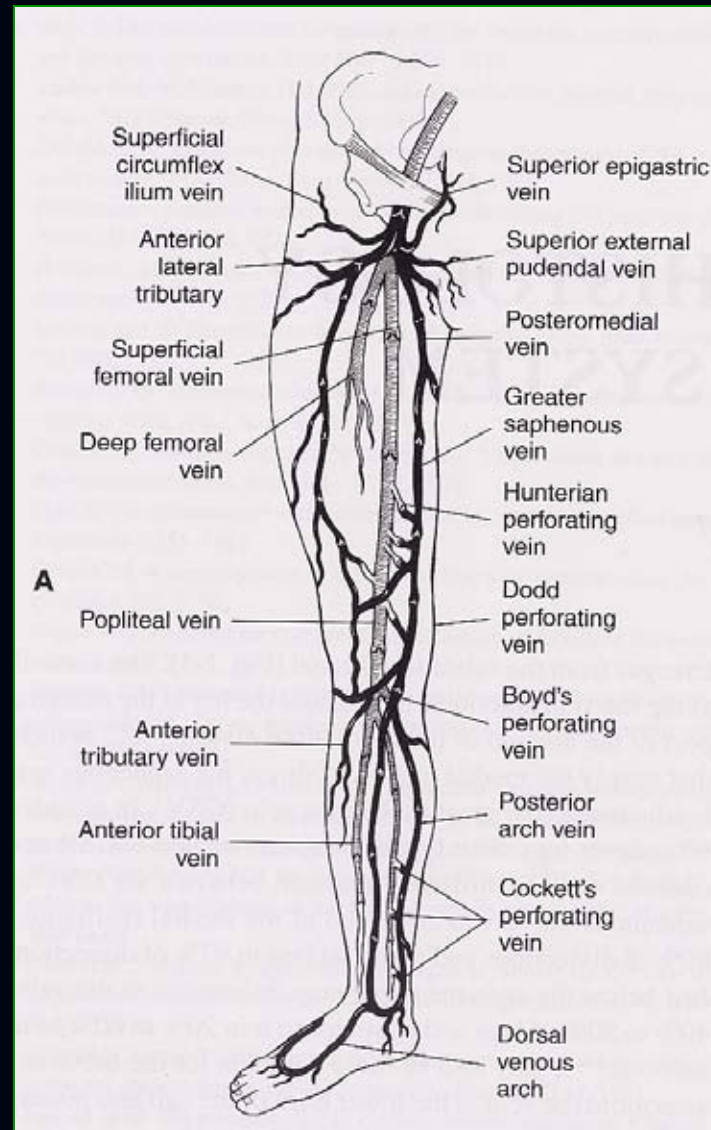







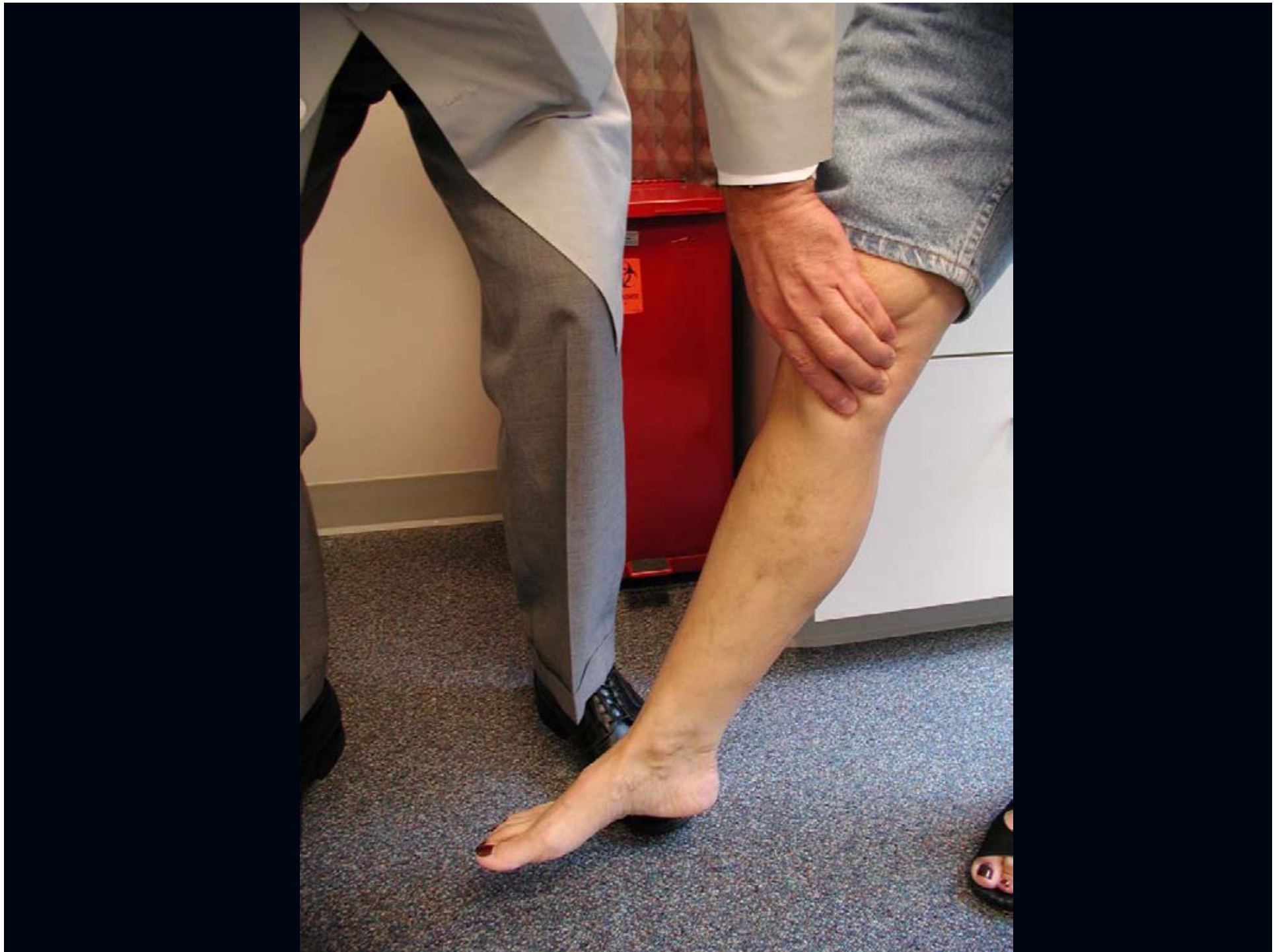
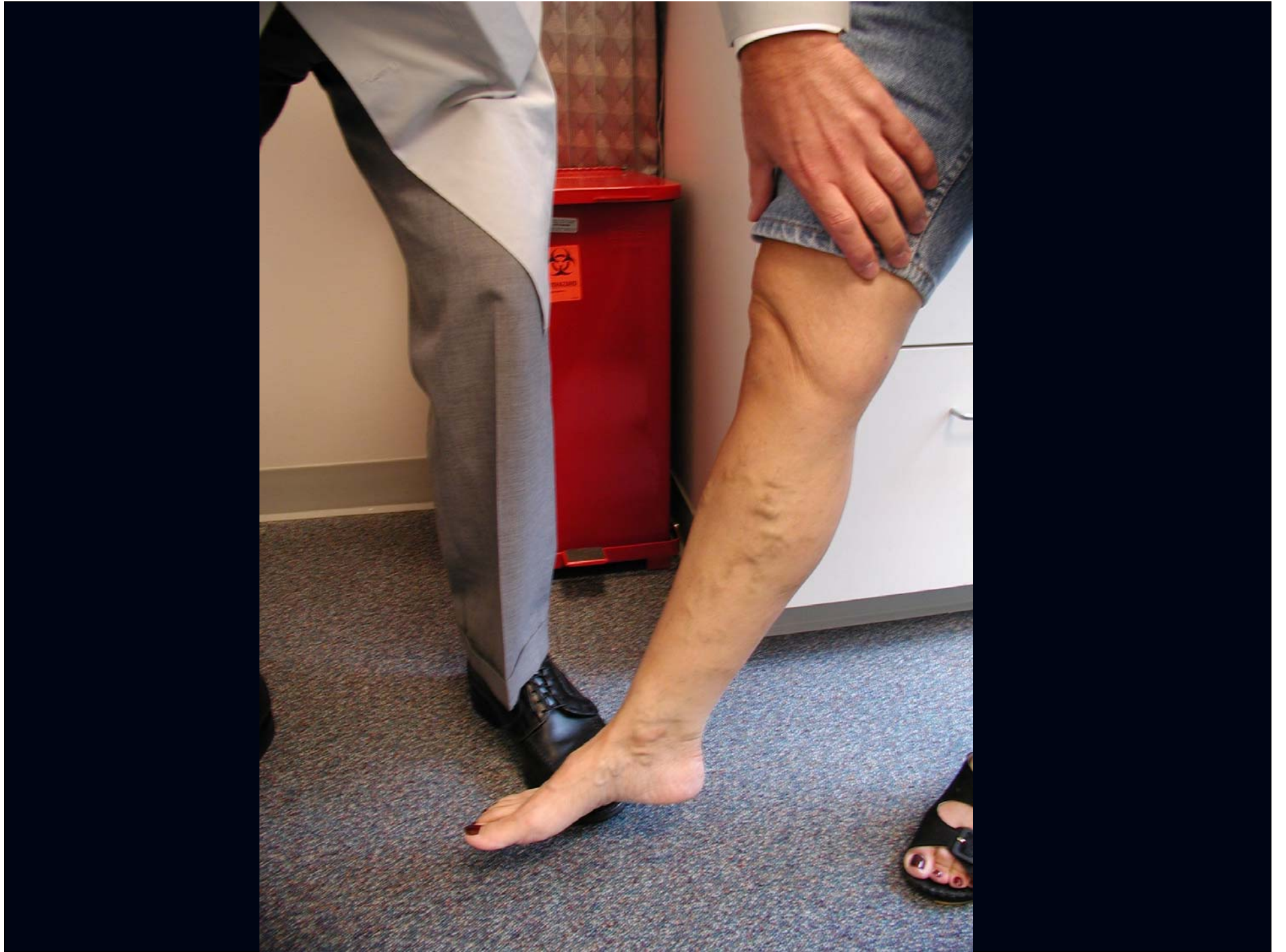# Tributaries



# Varicose Veins-Physical Exam

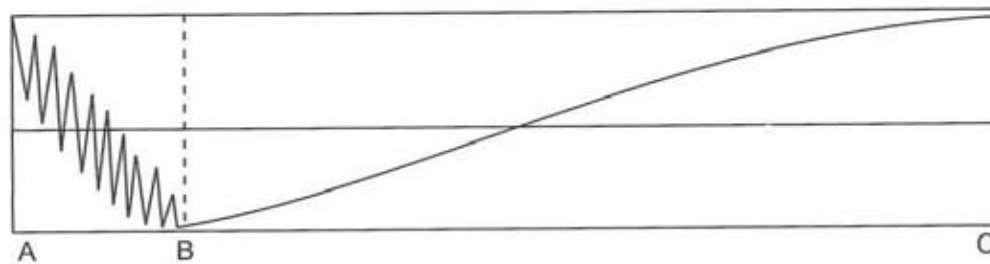
- Brodi-Trendelenburg Exam
- Perthes Exam



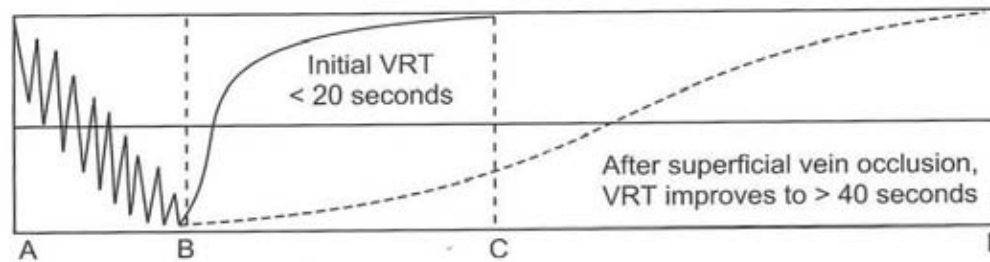


# Varicose Veins-Doppler Exam

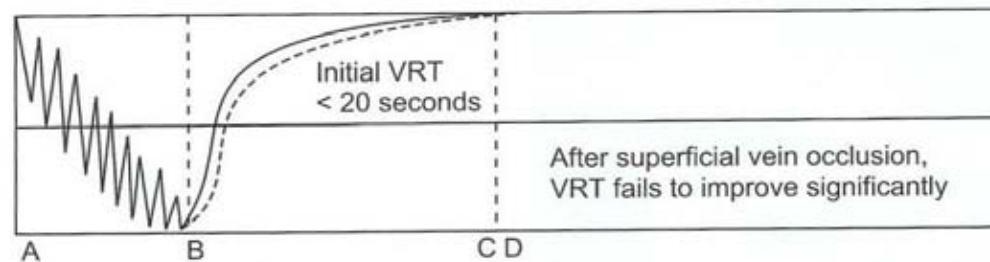
- Color Duplex Ultrasound Exam
- Hand Held Continuous Wave Doppler
- Venous PPG
- Venography



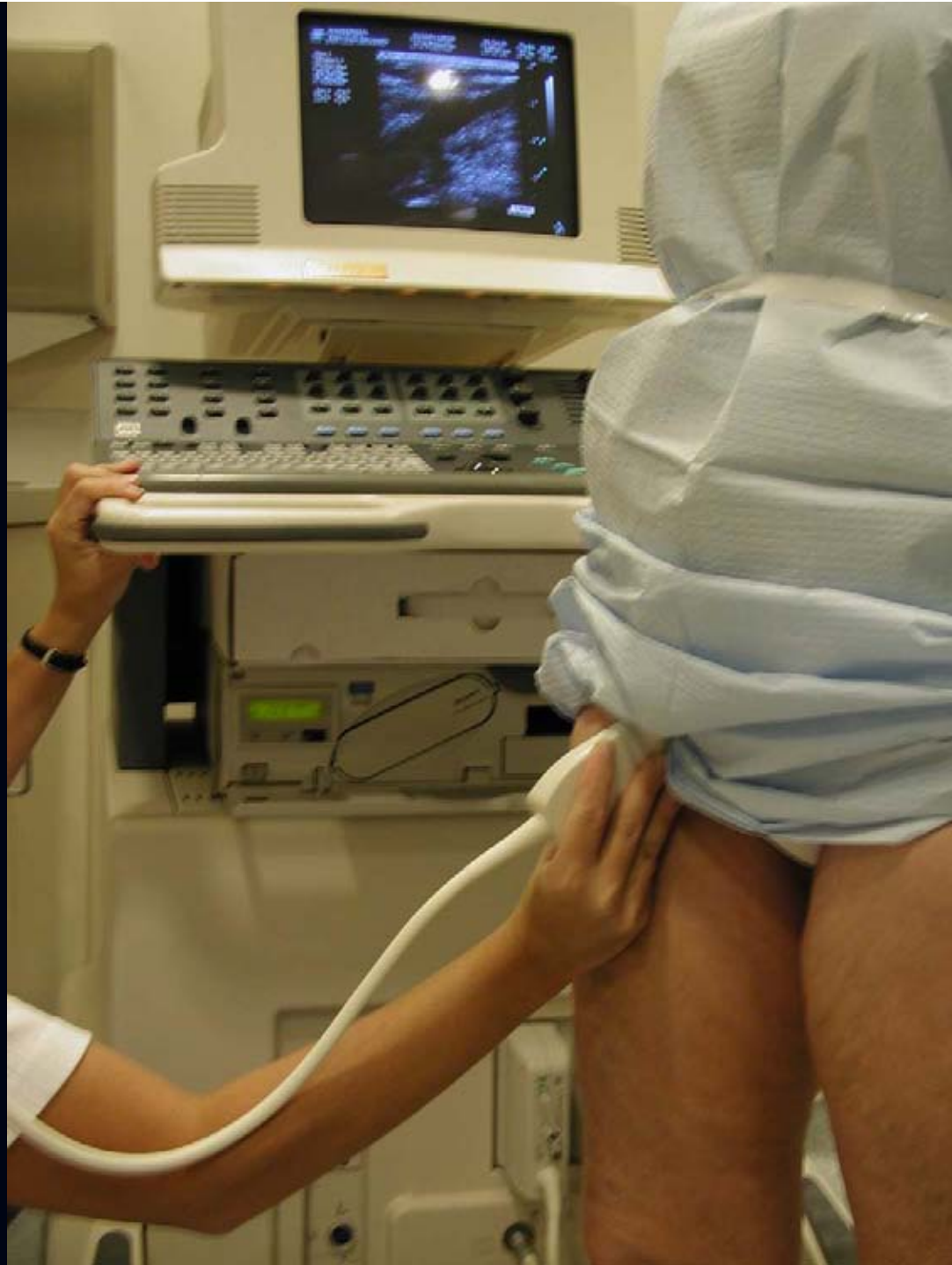**Figure 9-4.** Venous pressure at the ankle over time. (A) Calf muscle pumped 10 times to empty leg veins. (B) Relaxation of muscle pump. (C) As leg refills, venous pressure returns to baseline. The time from B to C is the VRT. A short VRT means that ambulatory venous hypertension exists.



**Figure 9-5.** Short VRT due to correctable superficial venous reflux. (A) Calf muscle pumped 10 times to empty leg veins. (B) Relaxation of muscle pump. (C) As leg refills via reflux, venous pressure returns rapidly to baseline. (D) After tourniquet occlusion of superficial incompetent (varicose) veins, reflux is obliterated and the leg refills normally.



**Figure 9-6.** Short VRT due to uncorrectable deep venous reflux. (A) Calf muscle pumped 10 times to empty leg veins. (B) Relaxation of muscle pump. (C) As leg refills via reflux, venous pressure returns rapidly to baseline. (D) Tourniquet occlusion of superficial veins fails to correct VRT, suggesting deep venous reflux.





ENH-OLD ORCHARD

331-54-2286

LT-4 PV266Nan

03 Nov 03

3:38:06 pm

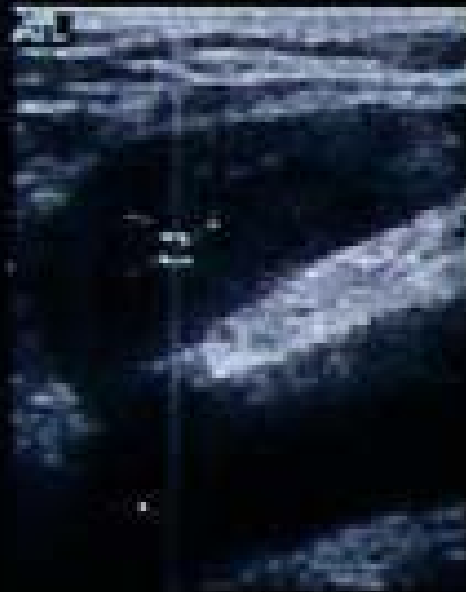
Tis 0.2

MI 0.9

Fr #77

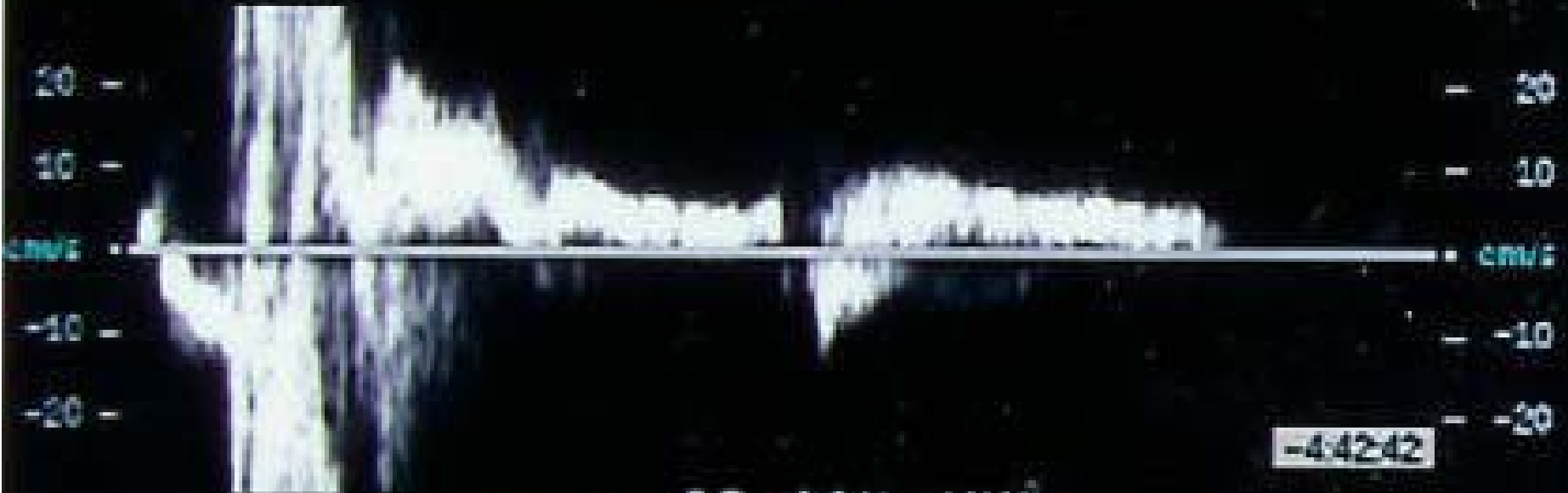4.8 cm

Map 1  
150dB/C 3  
Persist Med  
2D OptGen  
Fr Rate Max



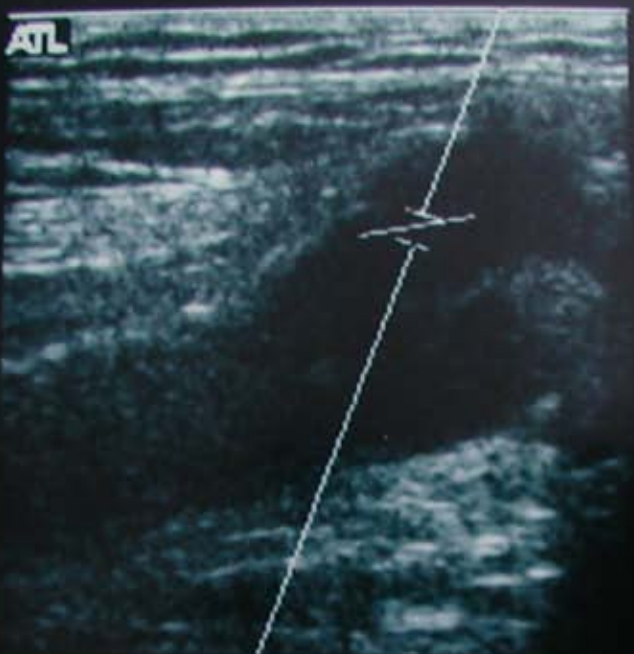-0  
-1  
-2  
-3  
-4

SV Angle 60°  
Dap 20 cm  
Size 20 mm  
Frag 4.0 MHz  
WF Low  
Dop 64% Map 4  
PRF 1515 Hz



RT GSV JUN

ap 1  
0dB/C 3  
ersist Med  
Opt:Gen  
Rate:Max



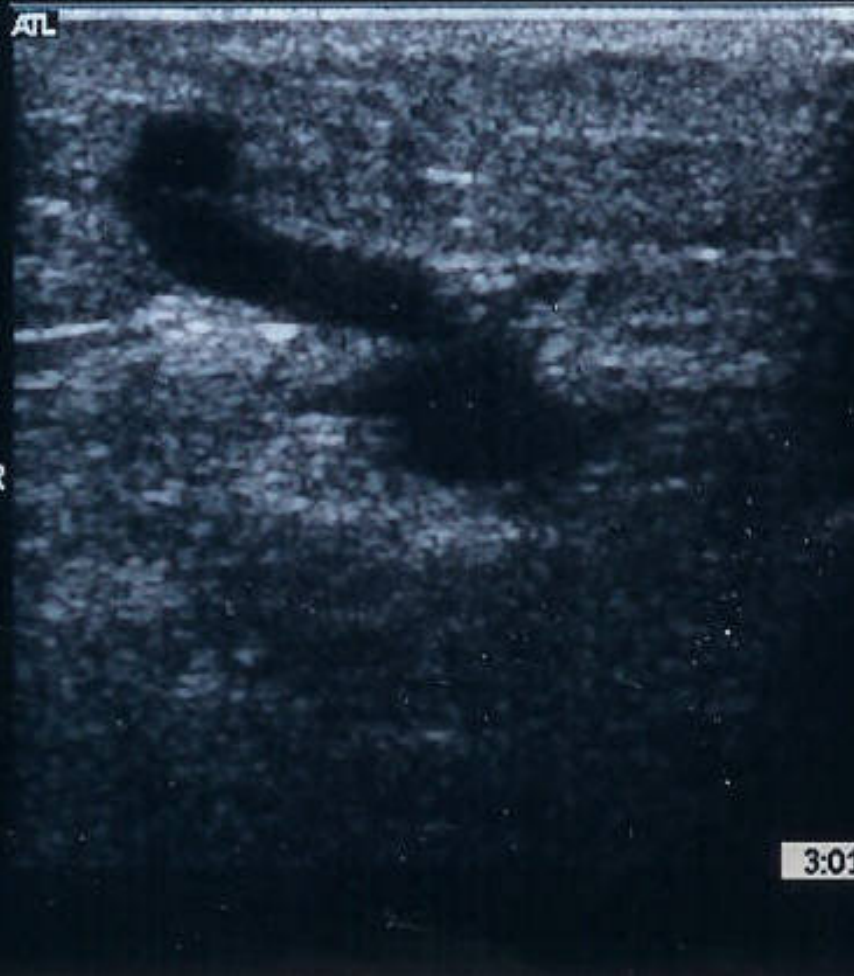-0  
-1  
-2  
-3

SV Angle 60°  
Dep 1.5 cm  
Size 2.0 m  
Freq 4.0 MHz  
WF Low  
Dop 64% Ma  
PRF 1515 Hz



Map 1  
150dB/C 3  
Persist Med  
2D Opt:Gen  
Fr Rate:Max

ATL



PERFERATTOR

OFF TIBIAL



I

3:01:19



# Summary

- History and Physical Exam provide the framework for decision making in patients
- Duplex Imaging provides the details to allow for selective treatment of diseased vein segments to minimized recurrence while preserving normal venous anatomy



**Welcome to the**

**13<sup>th</sup> Annual MIIT Interventional Radiology  
and Endovascular Therapy Seminar**



**October 28-30, 2004**

**Chicago Westin River North Hotel  
Downtown Chicago**

