





**13th Annual MIIT Interventional Radiology
and Endovascular Therapy Seminar**



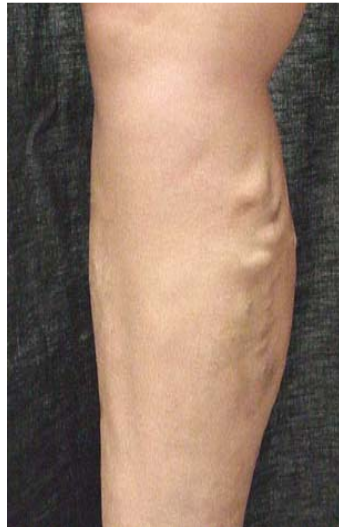Radiofrequency Ablation of the Saphenous Vein

Andy C. Chiou, M.D., MPH, FACS
Assistant Professor of Surgery and Radiology
University of Illinois College of Medicine at Peoria

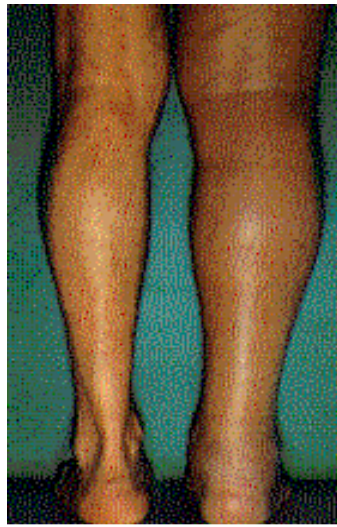



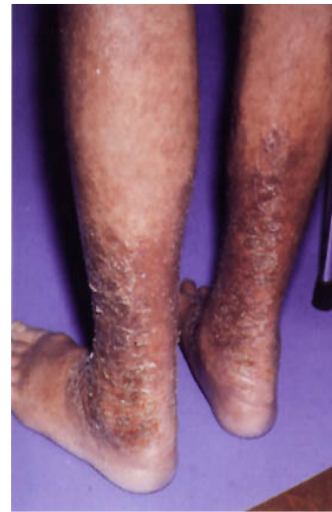Prevalence of Venous Disease



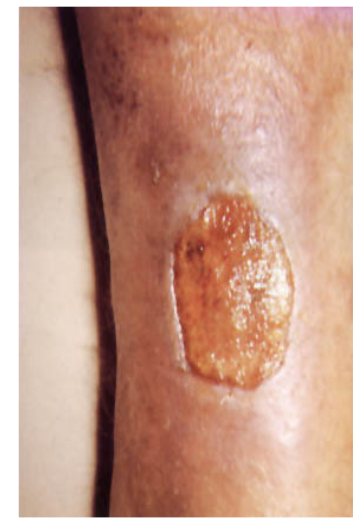Varicose Veins
20+ million



Swollen Leg
6 million





Skin Changes
1 million



Skin Ulcer
500,000







Radiofrequency energy is electrical energy delivered in a very condensed manner

When these waves come into contact with resistance, such as tissue, the waves cause excitement in the molecules of the solid, similar to what happens in home microwaves

This molecular excitement causes the solid surface or tissue to heat



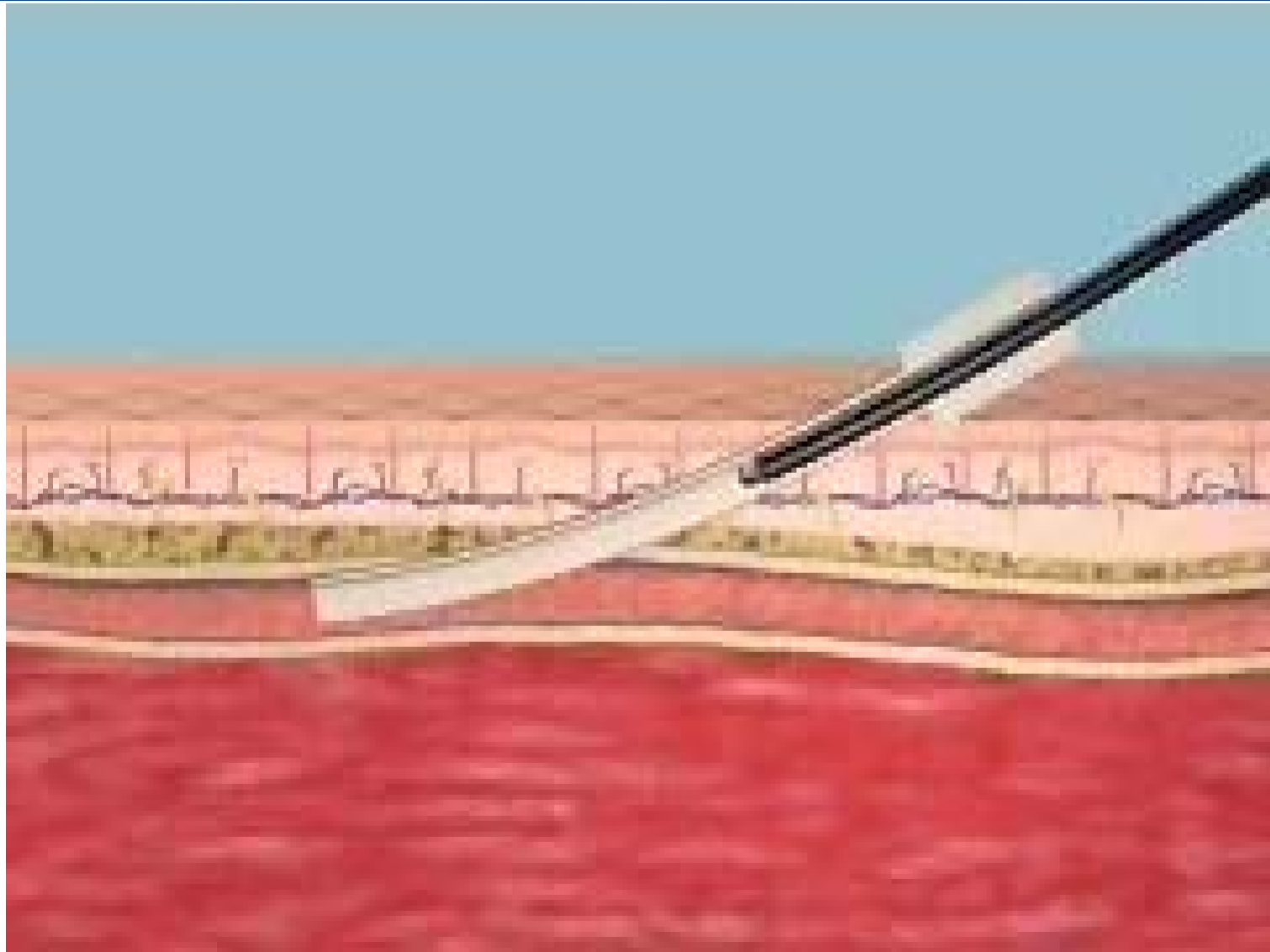






Radiofrequency Ablation of the Saphenous Vein: The Closure® System

Using a catheter- based approach, the Closure system delivers radio-frequency (RF) energy to the vein wall

RF energy creates *resistive heating* that contracts the vein wall collagen, thereby occluding the vein








Factors Affecting Collagen Contraction

- Temperature
 - Flow
 - Contact with vein wall (energy transfer)
- Impedance
 - Higher impedance shows good vein wall contact
- Pullback time
 - 2-3cm/min for transmural heating of vein wall
- Treatment location & anatomy
 - Collateral flow (side branches or perforators)
 - Junctions (SFJ)
 - Vein diameter

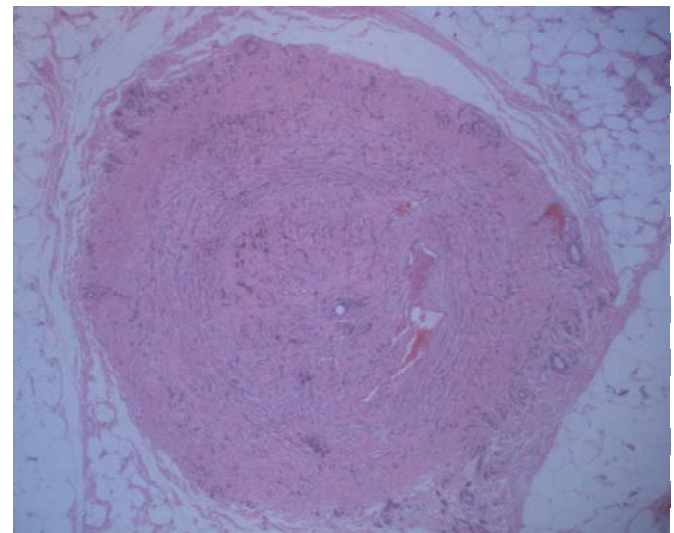
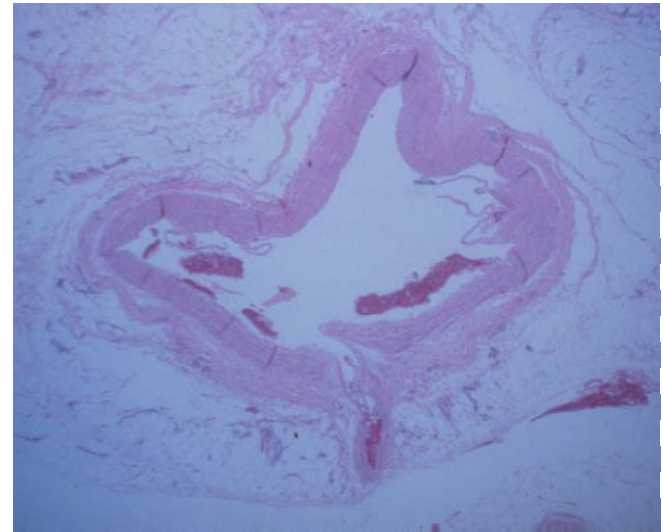






Collagen Contraction

Controlled heating of the vein wall causes:



- Shortening and thickening of collagen fibers
- Vein lumen diameter shrinkage
- Fibrotic sealing of the vessel









VNUS RF Generator



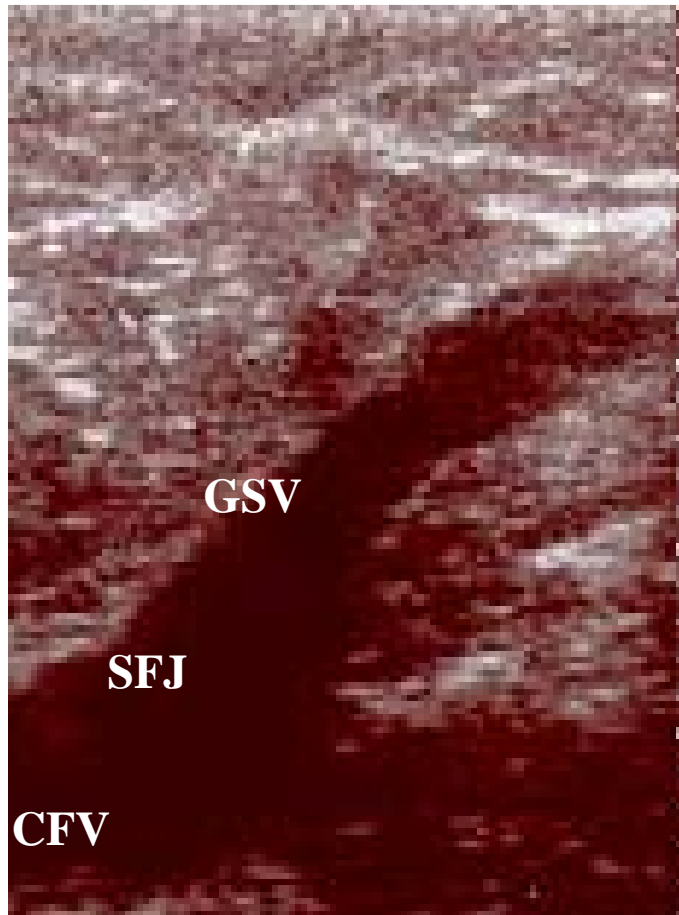


Catheters

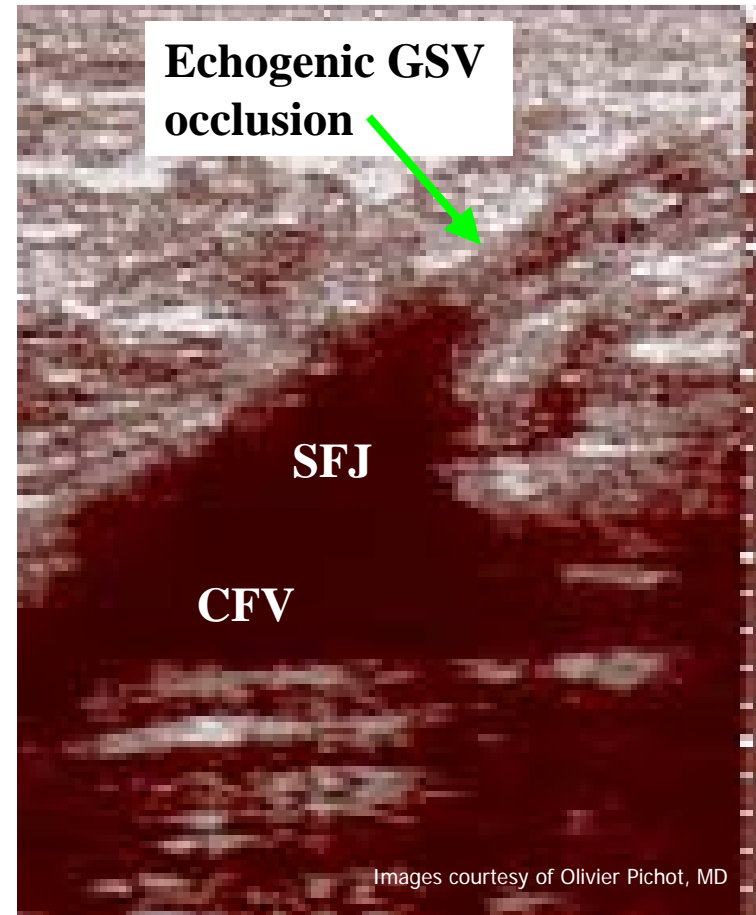





Postoperative Ultrasound Scan



Pre-treatment





Post-treatment

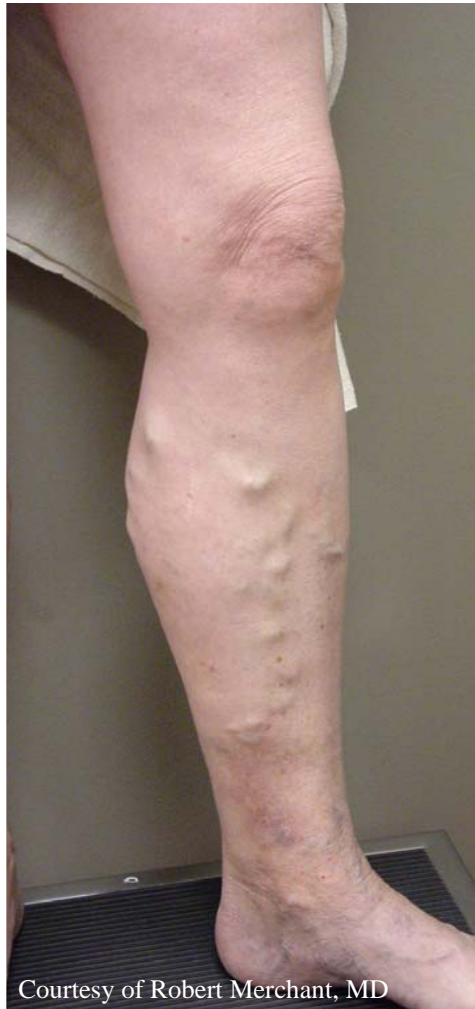

Post-Operative Instructions

- Frequent ambulation is encouraged
- Avoid heavy/strenuous exercise for a few days
- Avoid prolonged sitting or standing
- Compression stockings are optional
- Patient should return for duplex scan within 72 hours

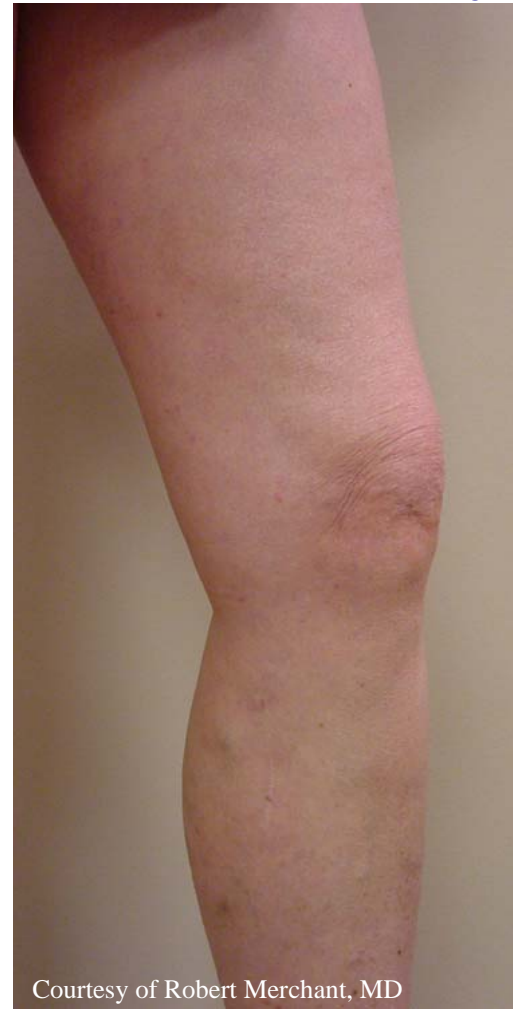

Closure[®] With No Adjunctive Phlebectomy




Courtesy of Robert Merchant, MD

Pre-treatment



Courtesy of Robert Merchant, MD

Typical results 2 weeks post-Closure





Clinical Results Summary

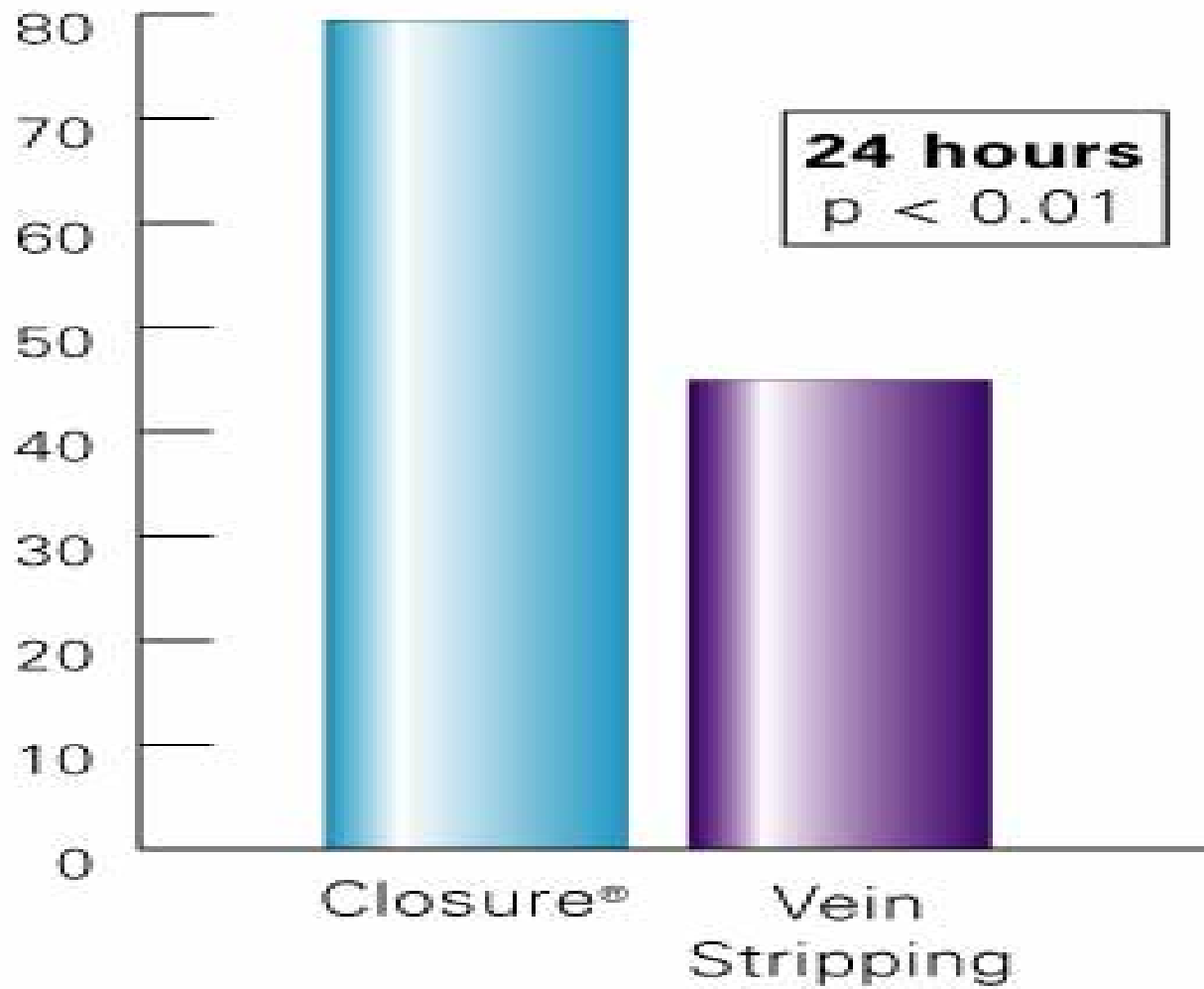
- 90% of treated limbs free of vein reflux¹ at 24 month follow-up
- 87% of treated limbs free of varicose veins¹ at 24 month follow-up
- Significant decrease in patient symptoms¹



	Follow-up Time Period			
	Pre-treatment N=319	6 months N=223	12 months N=232	24 months N=142
Leg Pain	83.1	5.8	3.9	3.3
Limb Fatigue	76.2	1.3	2.2	1.7
Edema	30.4	1.3	0.9	4.1
Pigmentation	21.6	8.5	9.9	7.4
Dermal Sclerosis	6.6	1.8	1.7	0.8

¹Merchant RF, DePalma RG, et al. Endovascular Obliteration of Saphenous Reflux – A Multicenter Study, Journal of Vascular Surgery, June 2002

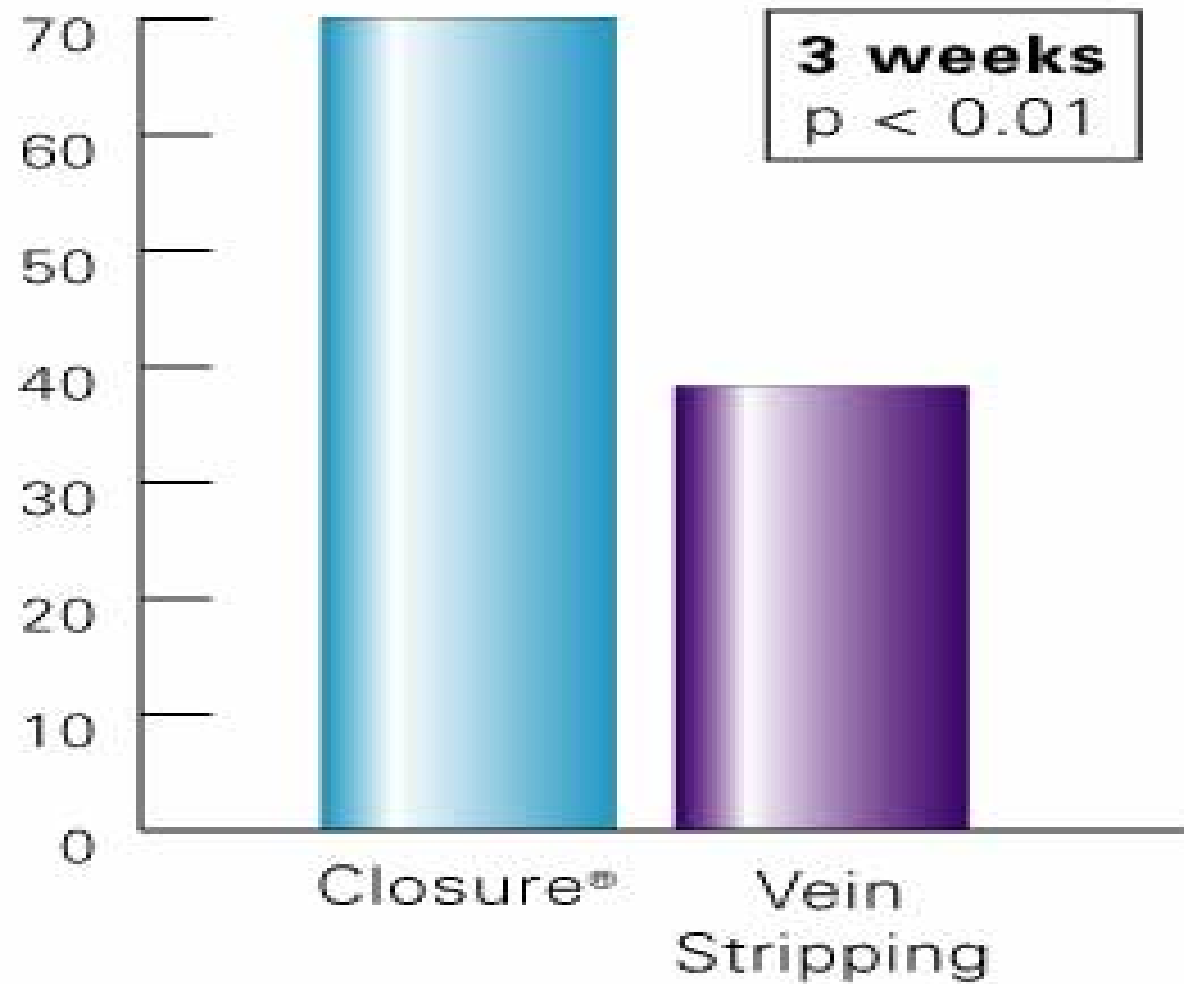




Return to Normal Activity





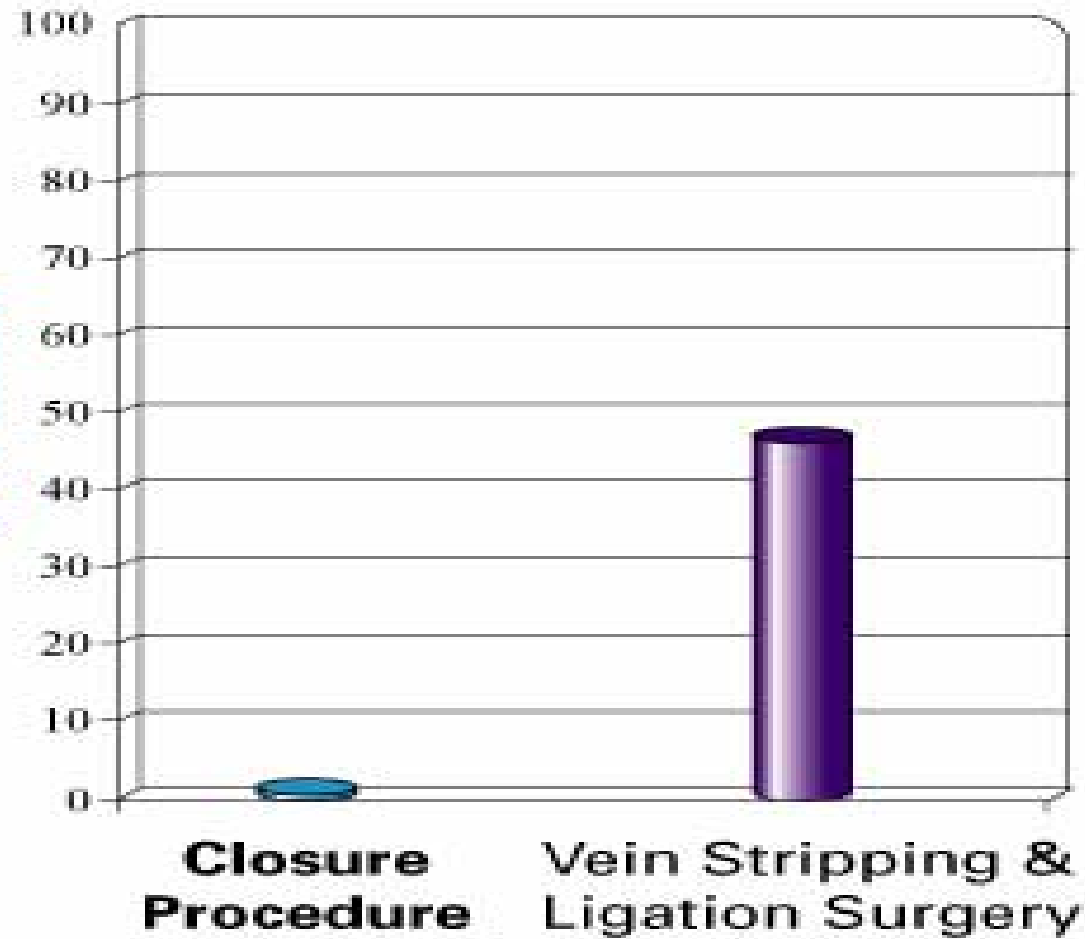
Freedom from Adverse Findings







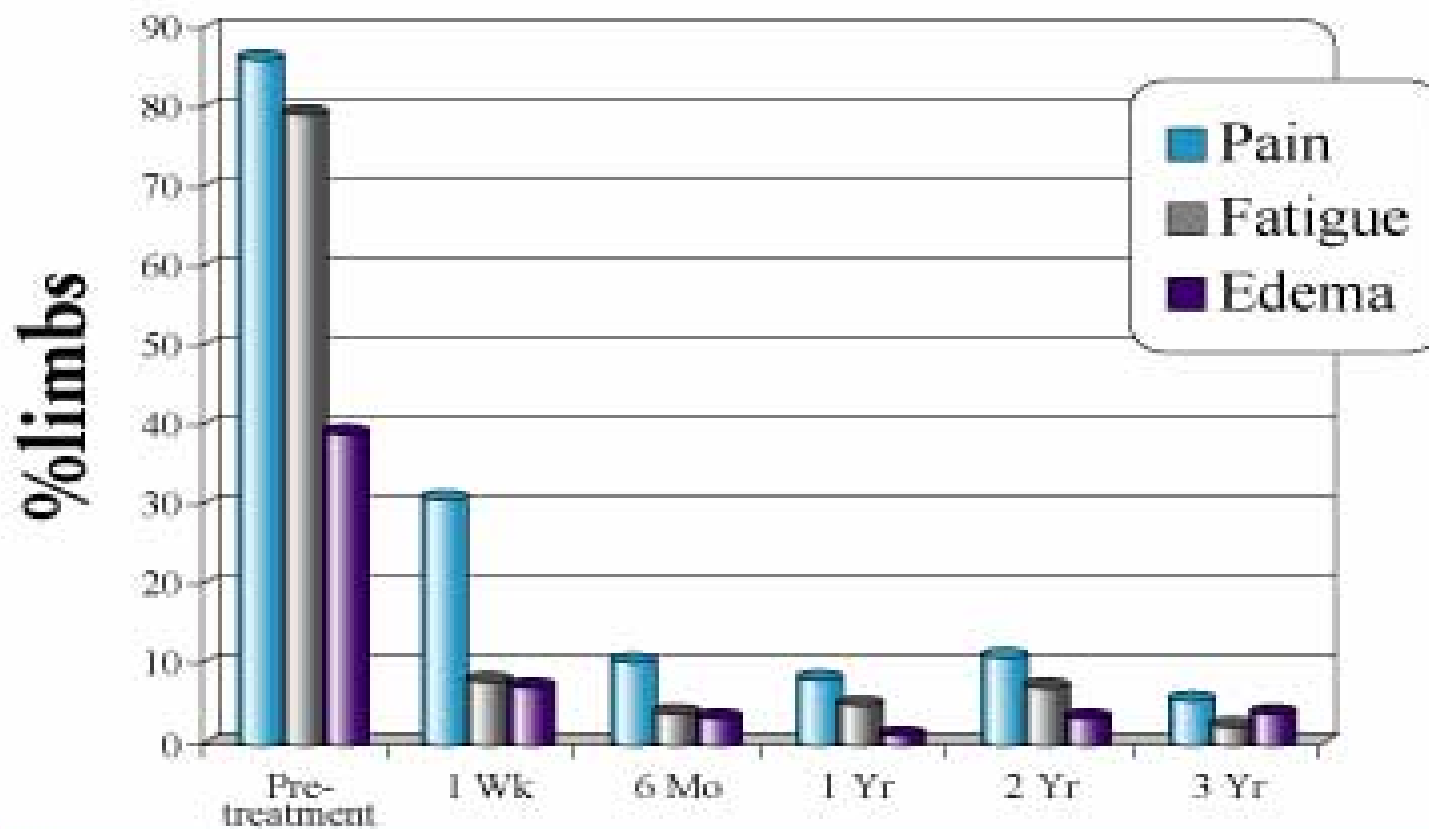
%limbs neovascularized



at 24 months





Patient Symptom Relief






Multiple Single Center Results

Reference	Follow-Up Term	Occlusion/ Reflux-Free Rate
Weiss ¹	2 years	90.5%
Rosenblatt ²	2 years*	95.7%
Kistner ³	1 year	97%
Whiteley ⁴	1 year	99.2%

*Up to 2 years.






Randomized Trials

- 3 randomized trials comparing Closure procedure vs. vein stripping
- Closure was superior than vein stripping in every statistically significant outcome²
 - less postoperative pain
 - less bruising
 - quicker recovery
 - higher quality of life scores
- 81% of Closure patients returned to normal activities within 1 day vs 47% of vein stripping patients²
- Closure patients returned to work more than 1 week sooner than vein stripping patients²

²Lurie, F, et al. Prospective randomized study of endovenous radiofrequency obliteration (closure procedure) versus ligation and stripping in a selected patient population (EVOLVE Study), J Vasc Surg 2003; 38(2): 207-14



Safety Summary

Indication:



The Closure System is intended for endovascular coagulation of blood vessels in patients with superficial venous reflux.

Contraindications:

Patients with thrombus in the vein segment to be treated

Potential Risks & Complications:



Potential complications include, but are not limited to the following: vessel perforation, thrombosis, pulmonary embolism, phlebitis, hematoma, infection, paresthesia, skin burns.



What about DVT?

- Hingorani et al reported in last month's JVS a DVT rate of 16% (12/73 GSV treated)
- No Pulmonary Emboli
- 10/12 DVT's resolved within 14 days on anticoagulation







Is this an outlier?

- In summation of the other reported data sets, DVT's were found in 0.4% (5/1125 GSV treated)
- Combined experience at three institutions
- Registry data indicate a DVT rate of 1%

Merchant RF, et al. Journal of Vascular Surgery 2002;35:1190-1206







Suggestions for decreasing DVT Risk

- Do not open the electrodes in the CFV
- Position the catheter tip at least 1cm, preferably 2 cm from the SFJ
- Do not rotate or move the limb once RF obliteration is initiated
- Empty the GSV with Trendelenburg and manual compression
- Avoid prolonged heating at or near the SFJ
- Compression stockings and early ambulation
- 72 hour duplex to detect DVT and allow for early treatment





Published Papers

Endovenous therapy for varicose veins of the lower extremities (in French).

Perrin M. *Ann Chir* 2004;129:248-57.

Evaluation of setpoint temperature and pullback speed on vein adventitial temperature during endovenous radiofrequency energy delivery in an in-vitro model.

Endovascular Surg 2004;38:167-74.

Varices des membres inférieurs traitées par radiofréquence (CLOSURE). Contrôle annuel des résultats : un suivi sur 3 ans (Longitudinal assessment at yearly intervals for lower limbs followed up three years after Endovenous radiofrequency obliteration (CLOSURE))

Perrin M. *Phlébologie* 2004;57:69-73.

Early experience with radiofrequency ablation of the greater saphenous vein.

Wagner WH, Levin PM, Cossman DV, Lauterbach SR, Cohen JL, Farber A. *Ann Vasc Surg* 2004;18:42-



Duplex ultrasound scan findings two years after great saphenous vein radiofrequency endovenous obliteration.

Pichot O, Kabnick LS, Creton D, Merchant RF, Schuller-Petroviae S, Chandler JG. *J Vasc Surg.* 2004; 39:189-

⁹⁵*Prospective randomized study of endovenous radiofrequency obliteration (Closure) versus ligation and stripping in a selected patient population (EVOLVES study).*

Lurie F, Creton D, Eklof B, Kabnick LS, Kistner RL, Pichot O, et al. *J Vasc Surg* 2003;38:207-14.





Intérêt de l'angiographie de la jonction saphéno-fémorale au cours de la destruction de la grande veine saphène par le système Closure (Sapheno-femoral junction angiography during great saphenous vein obliteration with VNUS Closure).

Lebard C, Zuccarelli F. Phlébologie 2002;55:263-8.

Duplex imaging analysis of the long saphenous vein reflux: basis for strategy of endovenous obliteration treatment.

Pichot O, Sessa C, Bosson JL. Int Angiol. 2002;21:333-6.

Ultrasound changes at the saphenofemoral junction and in the long saphenous vein during the first year after VNUS closure.

Fassiadis N, Kianifard B, Holdstock JM, Whiteley MS. Int Angiol 2002;21:272-4.

Endovascular obliteration of the greater saphenous vein: The Closure procedure.

Kistner RL, Jpn J Phlebol 2002;13:325-33.

Aspects échographiques de la jonction saphéno-fémorale après oblitération de la grande veine saphène par radiofréquence (Closure®).

Pichot O, Perrin M. Phlébologie 2002;55:329-34.

Initial experiences in endovenous treatment of saphenous vein reflux.

Sybrandy JEM, Wittens CHA. J Vasc Surg 2002;36:1207-12.

A novel endoluminal technique for varicose vein management: The VNUS Closure.



Fassiadis N, Kianifard B, Holdstock JM, Whiteley MS. Phlebology 2002;16:145-8.

Endovascular obliteration of saphenous reflux: A multicenter study.

Merchant RF, DePalma RG, Kabnick LS. J Vasc Surg 2002;35:1190-

6.





Endovenous obliteration versus conventional stripping operation in the treatment of primary varicose veins: A randomized controlled trial with comparison of costs.

Rautio T, Ohinmaa A, Perälä J, Ohtonen P, Heikkinen T, Wiik H, et al. J Vasc Surg 2002;35:958-65.

Comparison of endovenous radiofrequency versus 810nm diode laser occlusion of large veins in an animal model.

Weiss RA, Dermatol Surg 2002;28:56-61.
Controlled radiofrequency endovenous occlusion using a unique radiofrequency catheter under duplex guidance to eliminate saphenous varicose vein reflux: A 2-year follow-up.

Weiss RA, Weiss MA. Dermatol Surg 2002;28:38-42.

Surgical and endovascular treatment of lower extremity venous insufficiency.


Bergan JJ, Kumins NH, Owens EL, Sparks SR. J Vasc Interv Radiol 2002;13:563-

8
Endovenous obliteration with radiofrequency-resistive heating for greater saphenous vein insufficiency: A feasibility study.

Rautio TT, Perälä JM, Wiik HT, Juvonen TS, Haukipuro KA. J Vasc Interv Radiol 2002;13:569-75.
Closure of the greater saphenous vein with endoluminal radiofrequency thermal heating of the vein wall in combination with ambulatory phlebectomy: 50 patients with more than 6-month follow-up.

Goldman MP, Amiry S. Dermatol Surg. 2002;28:29-31.





Traitement de l'insuffisance veineuse superficielle par radiofréquence: Indications et résultats à moyen terme (Radiofrequency endovenous obliteration of the long saphenous vein: Indications and mid-term results).

Pichot O, Sessa C. *Phlébologie* 2002;55:51-8.

Endovenous techniques for elimination of saphenous reflux: A valuable treatment modality.

Weiss, RA. *Dermatol Surg* 2001;27:902-5.
Twelve and twenty-four month follow-up after endovascular obliteration of saphenous vein reflux - A report from the multi-center registry.

Kabnick LS, Merchant RF. *J Phleb* 2001;1:17-24.

Destruction de la grande veine saphène par le système Closure (Occlusion of greater saphenous vein by Closure system).

Lebard C, Zuccarelli F. *Phlébologie* 2001;54:285-91.
Twelve and twenty-four month follow-up after endovascular obliteration of saphenous vein reflux - A report from the multi-center registry.



Kabnick LS, Merchant RF. *J Phleb* 2001;1:17-24.

Destruction de la grande veine saphène par le système Closure (Occlusion of greater saphenous vein by Closure system).

Lebard C, Zuccarelli F. *Phlébologie* 2001;54:285-91.
Un procédé nouveau dans le traitement des varicèzes des membres inférieurs: la technique Closure®.

Perrin M. *Angéiologie* 2000;52:23-8.





Role of duplex imaging in endovenous obliteration for primary venous insufficiency.

Pichot O, Sessa C, Chandler JG, Nuta M, Perrin M. J Endovasc Ther 2000;7:451-

⁹*Defining the role of extended saphenofemoral junction ligation: A prospective comparative study.*

Chandler JG, Pichot O, Sessa C, Schuller-Petrovic S, Osse FJ, Bergan JJ. J Vasc Surg 2000;32:941-

⁵³*Duplex-guided endovascular occlusion of refluxing saphenous veins.*

Dauplaise TL, Weiss RA. J Vasc Tech 2001;25:79-82.

Treatment of primary venous insufficiency by endovenous saphenous vein obliteration.

Chandler JG, Pichot O, Sessa C, Schuller-Petrovic S, Kabnick LS, Bergan JJ. Vasc Surg 2000;34:201-

¹⁴*Closure of the greater saphenous vein with endoluminal radiofrequency thermal heating of the vein wall in combination with ambulatory phlebectomy: Preliminary 6-month follow-up.*



Goldman MP. Dermatol Surg. 2000;26:452-6.

Endovenous management of saphenous vein reflux.

Manfrini S, Gasbarro V, Danielsson G, Norgren R, Chandler JG, Lennox AF, et al. J Vasc Surg 2000;32:330-

42.





Published Book Chapters

Percutaneous radiofrequency ablations of varicose veins (VNUS Closure).
Whiteley MS, Holdstock In: "Vascular and Endovascular Challenges" Ed. Roger
M Greenhalgh. BIBA Publishing, BIBA Medical Ltd. – Copyright 2004 P361

"Traitement endovasculaire des varices des membres inférieurs"
M. Perrin, Encyclopedie Medico Chirurgicale: - Copyright 200343-161-C, Pages
1-11.

"Endovascular Therapy for Varicose Veins"
M. Perrin, Viguera Editores, S.L. Insuficiencia Venosa Cronica – Epidemiologia,
investigacion, diagnostico y tratamiento: - Copyright 2002Chapter 24: Pages
211-20

"Endovenous Saphenous Vein Ablation"
John J. Bergan, M.D. Mosby Inc. Advances in Vascular Surgery: - Copyright
2001 Volume 9; Chapter 9: Pages 123 -132.

Vascular and Endovascular Surgical Techniques: "Endovenous Vein Closure"
Andrew N. Nicolaidis, M.D. W. B. Saunders Company - April 2001 Vascular and
Endovascular Surgical Techniques 4th Edition

Vein Diagnosis & Treatment a Comprehensive Approach "RF Mediated
Endovenous Occlusion"
Editors, Robert A. Weiss, Craig F. Feied, Margaret A. Weiss, McGraw – Hill
Companies_ – Copyright 2001 Chapter 23: Pages 211-222.

Varicose Veins and Telangiectasias Diagnosis and Treatment
"Controlled Radiofrequency-Mediated Endovenous Shrinkage and Occlusion"
Editors, Mitchel P. Goldman, Robert A. Weiss, John J. Bergan, Quality Medical
Publishing, Inc. – Copyright 1999-2000 Chapter 12: Pages 217-224.



**13th Annual MIT Interventional Radiology
and Endovascular Therapy Seminar**



Thank You

