

Avoiding Complications in the UAE Patient



John A. Kaufman, M.D.



Dotter Interventional Institute
Oregon Health & Sciences University
Portland, Oregon

Is All UFE The Same?

- Varying indications
- Non-standardized procedure
 - Catheters and guidewires
 - Type, size, and shape of embolic materials
 - Site of delivery of embolic agent
 - Angiographic endpoint
- Non-standardized reporting of complications, follow-up

Overall Complication Rates

- No therapy, no consequence 0.25%
- Nominal therapy, no consequence 6.75%
- Required therapy, hospitalization < 48h 3%
- Major therapy, hospitalization > 48h 1.25%
- Permanent adverse sequelae 0%
- Death 0%

When Do Complications Occur?

- Intraprocedural
 - Angiographic
 - Embolization
- Post-procedure early (< 30 days)
- Post-procedure late

Angiographic Complications

- Anaphylaxis, contrast-induced renal failure, hematoma, pseudoaneurysm, arterial thrombosis, femoral nerve injury
- FIBROID registry; Spies Ob Gyn 2002
 - 3.75%
- Ontario UFE Trial; Pron JVIR 2003
 - 4.2%
- Pinto Radiology 2003
 - 25% (mostly puncture site hematoma)

High-Risk Patients

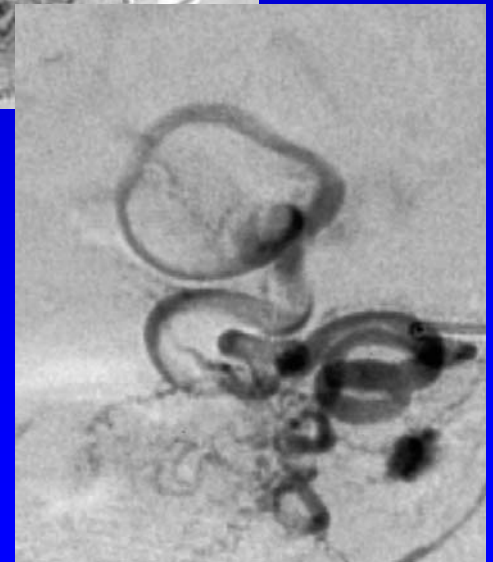
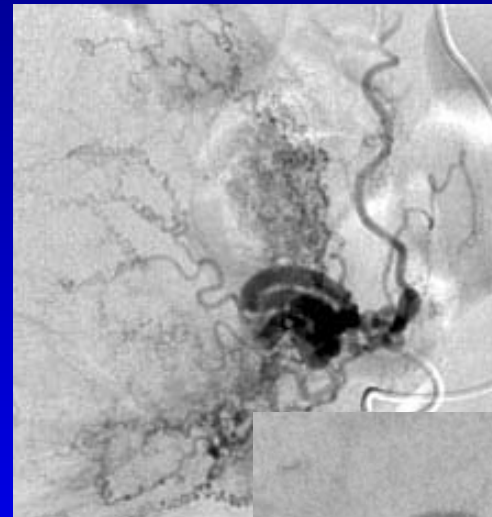
- Bleeding diathesis
- Hypercoaguable
- Renal insufficiency
- History of anaphylaxis
- Ehlers-Danlos

Embolization Complications: Spasm

- Related to catheter size, guidewire manipulation
 - More common with super-selective catheter placement
 - May result in false end-point
- 18% (Pinto 2003)
- Minimized with routine use coaxial catheter
- Intra-arterial NTG, lidocaine
 - Pre-procedure calcium channel blocking agents

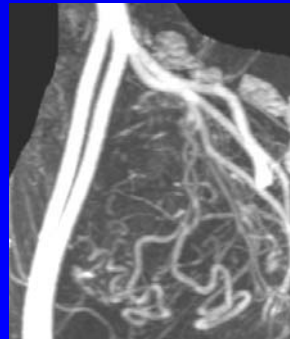
Uterine Artery Dissection/Perforation

- Dissection
 - 5% Pinto 2003
- Perforation
 - 0.5% Ontario UFE Trial 2003
 - Treated with coils
- Premature termination embolization
- No surgery, transfusion



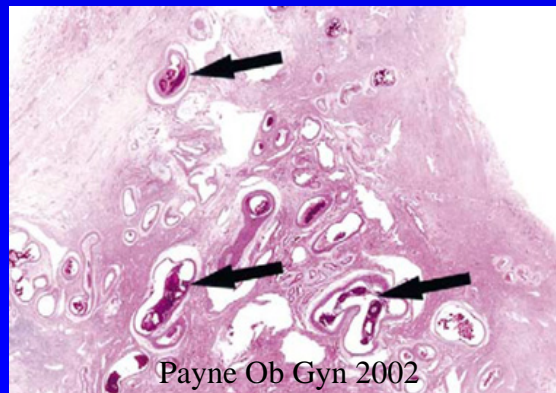
Avoiding Uterine Arterial Injury

- Microcatheters
 - “Soft” distal end
 - Balance between luminal diameter and trackability
- Long floppy tip guidewire
- Careful manipulation through tortuous arteries
- Pre-procedural MRA



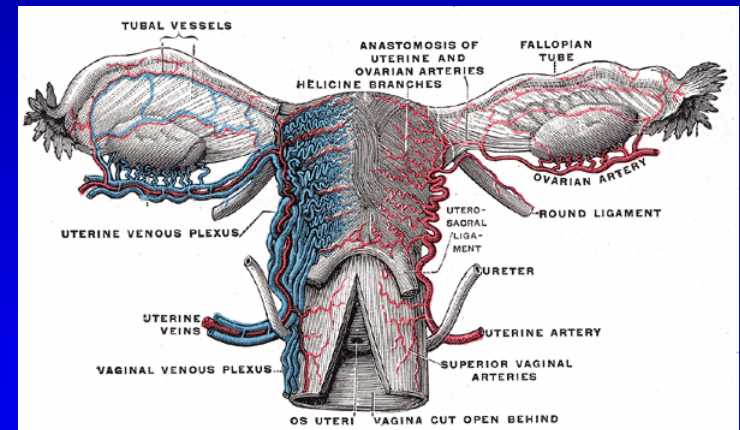
Non-Target Organ Embolization

- Ovary
- Cervix
- Vagina
- External genitalia
- Bowel
- Bladder
- Pelvic musculature
- Lower extremity



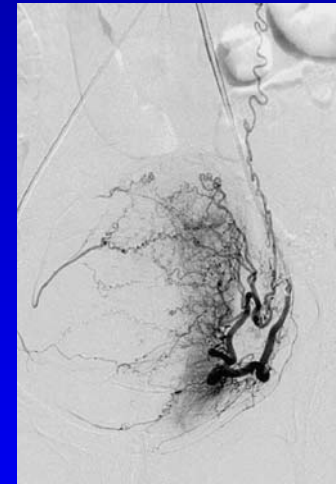
Utero-ovarian Anastomoses

- Up to 46% patients (Razavi Radiology 2002)
 - Multiple patterns
- Reversal of flow in ovarian artery (Wolanske JVIR 2003)
- Size variable
 - 500 microns in sheep model (Pelage CVIR 1999)



Ovarian Embolization

- 5% incidence symptomatic ovarian failure post embolization
 - Older patients
 - Large/multiple fibroids
 - May be transient (Amato Fert Steril 2001)
- Ryu AJR 2003
 - 6 patients
 - Decreased ovarian pulsatility index, resistive index in at least one ovary post embolization
 - 2 patients no ovarian flow at 28 weeks
 - 1 with symptoms of menopause

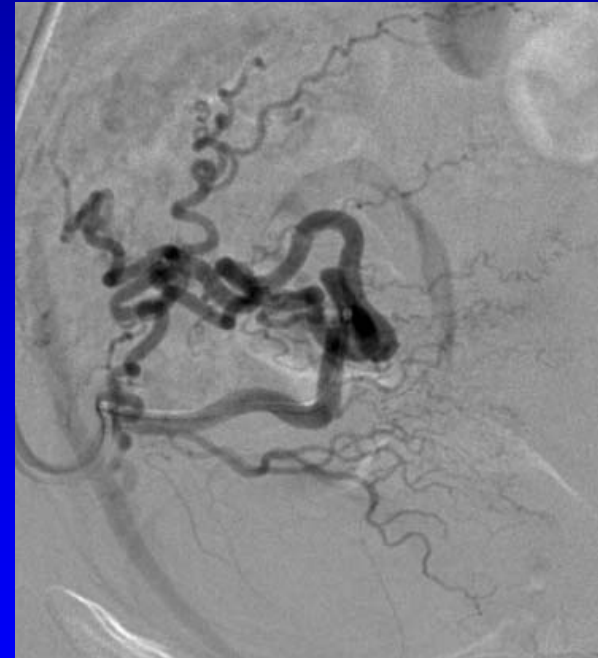


Avoiding Ovarian Embolization

- Large embolic material
 - 700 + micron spherical
- Selective uterine artery injections
 - Adequate volumes
- Catheter placement deep within uterine artery
- Monitor for reflux
 - Use roadmap mode

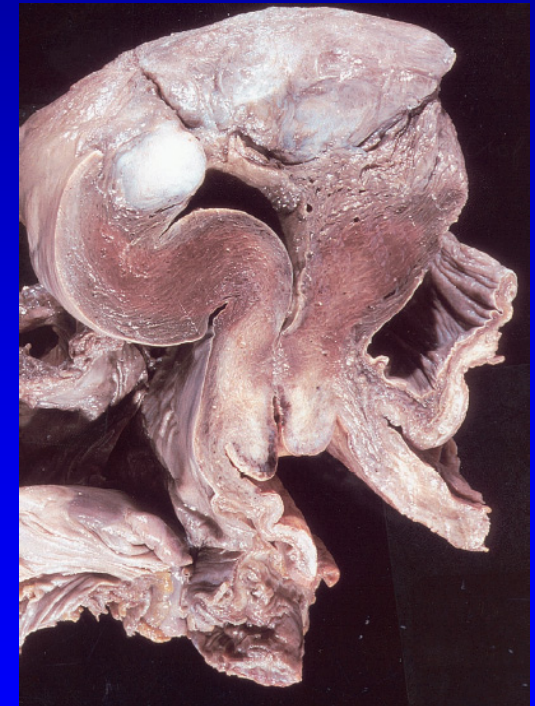Cervico-vaginal Embolization

- Clinical manifestations
 - Orgasmic dysfunction
 - Up to 2% (Katsumori AJR 2003)
 - Vaginal wall/labial ischemia/necrosis (case reports)
- Cervical/vaginal branches of uterine artery
- Minimize risk using same approach as for protection of ovaries



Uterine Ischemia/Necrosis

- Case reports only
 - 0% in most series
 - Clinical presentation days to weeks later
- Related to size and number of particles
 - Bok JVIR 2003
 - Fatal sepsis following UAE
 - 11 vials 500-700 Embospheres
 - ¼ vial 700-900 Embospheres

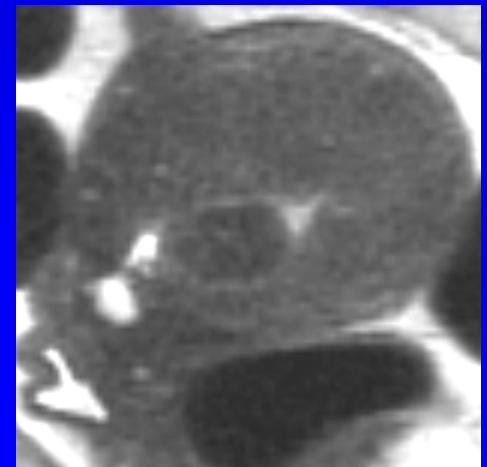


Post-Embolization Syndrome

- Reported 25 - 30% patients
 - Low grade fevers, leukocytosis
- Almost all are have fatigue, malaise
- May be related to volume of infarcted tissue
 - Trend to longer recovery with fibroids > 10 cm
 - Katsumori AJR 2003
- No known preventative measures

Expulsion of Fibroid Tissue

- 2 – 4% of patients
 - Pain, bleeding, fever; 1 yr/+ post embolization
- Not related to embolic technique/material
- More likely with submucosal/intracavitary fibroids
- Pre-procedure imaging of fibroids



Infectious Complications

- Endometritis 0.5% (Spies OB Gyn 2002)
- Vulvo-vaginitis 2% (Pinto Radiology 2003)
- Pyosalpinx, pyometrium anecdotal
- Urinary tract 1-5% (Spies, Pinto)

Prevention of Infections

- Preprocedural imaging
 - Hydrosalpyinx
- Delay embo if recent salpingitis/endometritis/UTI
- Antibiotic prophylaxis
 - No prospective evidence of efficacy
- Education of patient
 - Return for symptoms of infection
 - Possibility of delayed infection

Unusual Complications

- Vesicouterine fistula
 - Sultana Am J Obstet Gynecol 2002
- Uterine prolapse 16 months post UAE
 - Bedaiwy Int Urogynecol J Pelvic Floor Dysfunct 2004

Case report

Spontaneous multiple pregnancy after uterine artery embolization for uterine fibroid: case report

Arianna D'Angelo^{a,*}, Nazar N. Amso^a, Andrew Wood^b

^aDepartment of Obstetrics and Gynaecology, University Hospital of Wales College of Medicine, Heath Park, Cardiff, Wales CF14 4XN, UK

^bDepartment of Radiology, University Hospital of Wales College of Medicine, Heath Park, Cardiff, Wales CF14 4XN, UK

Received 20 November 2002; received in revised form 12 March 2003; accepted 3 April 2003

Complications of UAE

- Most severe complications avoided by careful patient selection, embolization technique
- Infectious complications require early recognition and treatment
 - Can occur months after UAE
- Overall a safe procedure